

Interventional Radiology GRAND ROUNDS

Topic: Peripheral Arterial Disease

An estimated 1 million Americans develop symptoms of peripheral arterial disease (PAD) each year. Patients with chronic arterial occlusion of the lower extremities often present with the pain of exercise-induced intermittent claudication, usually localized to the calf but also seen as pain in the buttocks or thighs. More advanced cases may present with exercise-induced numbness, rest pain, tissue loss, infection or gangrene.

More than 70 percent of patients with PAD will experience either no change or an improvement in symptoms after five to 10 years of conservative management. Twenty percent to 30 percent of patients develop more severe symptoms, which require intervention. Fewer than 4 percent of patients will require amputation.¹

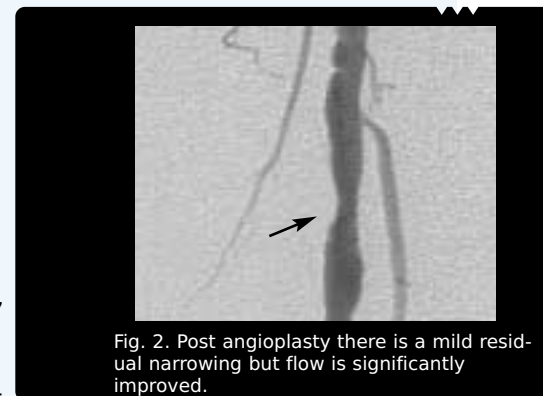
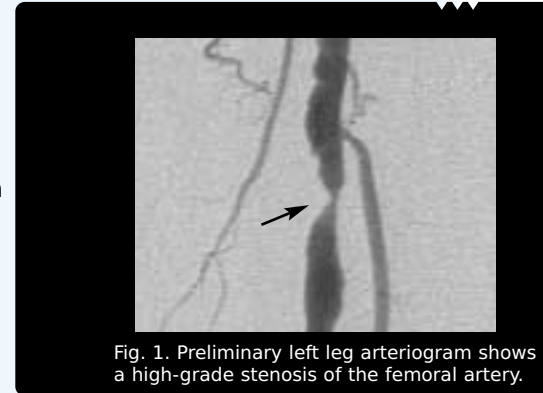Despite the relatively benign prognosis for the affected limb, the presence of PAD is, in most cases, a sign of systemic atherosclerosis, which puts these patients at higher-than-average risk for cardiovascular morbidity and mortality.

Prevalence

In men, the onset of PAD symptoms often occurs in the 50s; onset in women is typically 10 years later. Studies have indicated that currently as many as 5 percent of men and 2.5 percent of women over the age of 60 have symptoms of PAD. The prevalence is higher when sensitive noninvasive tests are used to make the diagnosis in asymptomatic individuals. The prevalence of the disease increases with age, and in studies of males, its predominance appears to diminish after the age of 70. Intermittent claudication is seen in approximately 15 percent of PAD patients over the age of 50; approximately 1 percent exhibit critical limb ischemia.¹

Case History

A 74-year-old diabetic male presented with a non-healing left foot ulcer. The ulcer had not responded after three months of medical management. The ankle-brachial index of the left foot was 0.54, in the advanced claudication range. His great toe pressure was only 26mmHg, in the ischemic range. An arteriogram demonstrated a focal stenosis of the superficial femoral artery and some moderate lesions in the calf vessels. After simple balloon angioplasty, the femoral stenosis improved significantly and toe pressure improved to 80mmHg. His ulcer healed after a few more weeks of local wound therapy.



Risk Factors

Although the precise mechanism of PAD is not known, there are a number of well-recognized risk factors: smoking, hypertension, diabetes, hyperlipidemia, obesity, inactive lifestyle and family history of vascular or heart disease being the most common.

Diagnosing PAD

Diagnosis begins with a careful history and physical examination. In some PAD patients, sites of involvement may be detected by obvious pulse deficits or abnormalities in skin color or temperature. However, relying on a history and exam alone is not recommended. In one study, 44 percent of PAD diagnoses were false positive and 19 percent were false negative when history and physical exam alone were used.²

Referral for Interventional Radiology Evaluation

Indications for peripheral angiography:

1. Incapacitating claudication interfering with work or life style that is unresponsive to conservative therapy.
2. Limb salvage for limb-threatening ischemia manifested by rest pain, nonhealing ulcer, infection or gangrene.

There are a number of noninvasive options that more accurately diagnose PAD, including:

- Ankle-brachial index (ABI), is the gold standard to establish diagnosis and serve as a baseline measure for patient follow-up. Measurements may be taken before and after exercise to assess the dynamics of intermittent claudication.
- Measurement of toe pressure may be particularly helpful in diabetics whose disease tends to be more severe and frequently involves calcification of the media, making ABI measurements inaccurate due to the inability to compress the ankle vessels.
- Segmental pressures and pulse volume recordings are used to measure pressures at levels in the ankle, calf, above the knee, and thigh.
- Duplex and color flow ultrasound scanning, normally reserved for patients who are scheduled for balloon angioplasty or other interventions,

enables stenotic segments to be localized for treatment planning.

- MR angiography is an evolving imaging modality that is useful as a diagnostic tool, particularly in patients who cannot receive iodinated contrast agents due to renal disease.

Treatment Options

Conservative treatment options, including cessation of tobacco use, exercise programs, and modifications in lipoprotein and cholesterol abnormalities are the first line of defense against PAD.

Rheologic Agents

Pentoxifylline, an oral methylxanthine derivative, is the only drug currently approved by the FDA for the symptoms of claudication. The drug is believed to decrease blood viscosity and increase erythrocyte flexibility, which improves microcirculation. A critical review of trials with pentoxifylline, however, concluded that the benefits of the drug are unpredictable and may not justify the added expense for many patients.³

Antiplatelet/Antithrombotic Therapy

Studies have shown that aspirin therapy may modify the natural history of chronic lower extremity PAD; it also has been suggested that administering aspirin to patients with PAD may be reasonable to prevent death and disability from stroke and myocardial infarction as complications of underlying disseminated atherosclerosis.¹

Percutaneous Endovascular Therapies

Percutaneous transluminal angioplasty remains the gold standard among nonsurgical, endovascular therapies for PAD when lifestyle modifications and drug therapies fail. Focal lesions of the abdominal aorta, iliac arteries and superficial femoral arteries are highly amenable to this technique. Small vessels distal to the knee may also be treated successfully, although percutaneous intervention is generally reserved for patients with limb-threatening

ischemia. The most recent advance in the percutaneous treatment of PAD has been the introduction of metallic, endovascular stents placed within the lumen of the artery to maintain patency. In select patients with acute arterial occlusions, intra-arterial thrombolysis also may be an option.

Surgical Interventions

Surgery for PAD is generally reserved for those symptomatic patients who don't respond to these more conservative treatments and whose vascular anatomy and arterial blockages are not optimal for endovascular therapy. Because of frequent concomitant cerebral and coronary vascular disease, the risks of post-operative morbidity and mortality remain significant in this population of patients.⁴

PAD Treatment Options

Lifestyle Modifications

- Tobacco cessation
- Exercise
- Lipid-lowering diet

Medical Management

- Rheologic agents
- Lipid-lowering agents
- Antiplatelet/Antithrombotic therapy

Percutaneous Endovascular Therapies

- Angioplasty
- Endovascular stents
- Intra-arterial thrombolysis

Surgery

- Endarterectomy
- Bypass

Strategies for normalizing PAD risk factors

- **Smoking cessation.** In one study, 16 percent of patients with claudication who did not quit smoking progressed to rest pain within seven years. Rest pain, which is associated with significant disability and a high risk for gangrene, did not occur in any of the patients who quit smoking.⁵ Abstinence from tobacco in this patient population also has been shown to markedly decrease the incidence of myocardial infarction and stroke, and improve survivals.
- **Diabetes management.** A number of studies have shown an association between diabetes and PAD. In one population-based study, nearly 25 percent of patients undergoing lower extremity revascularization were diabetic.⁶
- **Hyperlipidemia management.** The recent National Cholesterol Education Panel guidelines recommend that patients with PAD be treated with dietary and pharmacologic therapy to achieve a low-density lipoprotein cholesterol less than 100 mg/dL.⁷
- **Exercise.** In one study, 88 percent of patients completing a prescribed exercise program reported they were able to increase their walking distance by at least 100 percent.⁸

References:

1. Weitz J, Byrne J, et al. Diagnosis and treatment of chronic arterial insufficiency of the lower extremities: A critical review. *Circulation* 1996;94:3026-3049.
2. Marinelli M, Beach K, Glass M, et al. Noninvasive testing vs. clinical evaluation of arterial disease: A prospective study. *JAMA* 1979;241:2031-2034.
3. Radack K, Wyderski R. Conservative management of intermittent claudication. *Ann Intern Med* 1990;113:135-146.
4. Coffman J. Intermittent claudication: Not so benign. *Am Heart J* 1986;112:1127.
5. Jonason T, Bergstrom R. Cessation of smoking in patients with intermittent claudication. Effects on the risk of peripheral vascular complications,

- myocardial infarction and mortality. *Acta Med Scand* 1987;221:253-260.
6. Farkouh M, Rihal C, Gersh B, et al. Influence of coronary heart disease on morbidity and mortality after lower extremity revascularization surgery: A population-based study in Olmsted County, Minnesota (1970 – 1987). *J Am Coll Cardiol* 1994;24:1290-1296.
 7. Expert Panel on Detection, Evaluation, and Treatment of High Blood Cholesterol in Adults. Summary of the second report of the National Cholesterol Education Program (NCEP) expert panel on detection, evaluation and treatment of high blood cholesterol in adults (Adult Program Panel II). *JAMA* 1993;269:3015.
 8. Williams L, Ekers M, Collins P, Lee J. Vascular rehabilitation: Benefits of a structured/risk modification program. *J Vasc Surg* 1991;143:320-326