

Interventional Radiology GRAND ROUNDS

Topic: Image-Guided Percutaneous Needle Biopsy

Percutaneous needle biopsy has been a mainstay of oncologic diagnosis for more than two decades, since the advent of ultrasound and computed tomography (CT). The basic principles of fine needle aspiration and core needle biopsy can be applied to almost any site in the body, with subtle differences in technique depending on the organ being investigated and the imaging modality utilized.

While excisional biopsy is still appropriate in certain cases, including diagnosis of breast and brain tumors, percutaneous needle biopsy has

become the standard of care in the diagnosis of most tumors throughout the body. Needle biopsy also is used to diagnose non cancerous conditions, such as infection.

Advances in imaging techniques have led to greater precision in targeting tumors and allowing for minimally invasive percutaneous biopsy of tissue inaccessible to minor surgery, such as lung lesions. Percutaneous biopsy also is beneficial in the staging of patients with cancer, particularly when another treatment method may be more appropriate than surgical resection.

Advantages of percutaneous biopsy over surgical excisional biopsy include time and cost savings and reduction in morbidity. Complication rates of percutaneous biopsy vary according to the organ studied, but overall are less than 0.1 percent.¹

Case History

A 55-year-old woman with a history of tobacco use presented to her physician for a routine physical examination. Chest radiography demonstrated a vague pulmonary nodule. Further evaluation with CT demonstrated a 2 cm nodule (arrowheads) in the anterior mediastinum (**Fig. 1**). In order to avoid puncture of the internal mammary vessels (long arrow), a guiding needle was passed along the lateral margin of the sternum (s) to the surface of the lesion (**Fig. 2**). A 22 gauge needle was then passed through the guide into the nodule. A diagnosis of adenocarcinoma was established on pathological examination.

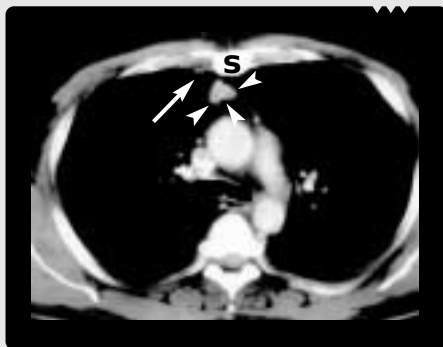


Figure 1

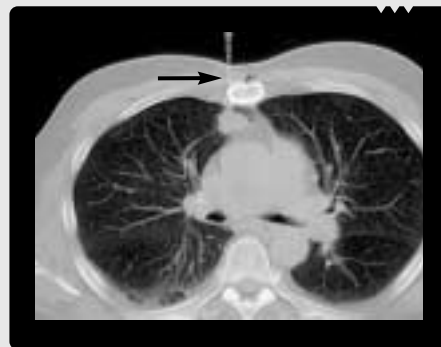


Figure 2

Patient Preparation

Most procedures can be performed using intravenous sedation and local anesthesia. General anesthesia may be preferable in some cases, including pediatric patients. All patients require observation for a few hours following the procedure.

Pertinent patient history includes bleeding dyscrasias and use of blood thinning medications, including aspirin. Contraindications for biopsy are an uncorrected coagulopathy and lack of a safe route to pass a needle.

Image Guidance and Technique

Most patients are referred to an interventional radiologist for percutaneous biopsy having had at least one cross-sectional imaging study. The lesion in question should be identifiable on ultrasound, CT or magnetic resonance (MR) imaging. Image guidance varies according to the size, location and visibility of the lesion. Most intra-abdominal lesions can be approached using either ultrasound or CT. While fluoroscopy still is utilized for lung biopsy, CT is preferred for biopsies of the lung, bone and spine, and for base-of-skull lesions. Recent advances in MR have made this imaging modality increasingly useful, particularly for dome-of-liver and adrenal masses, where an oblique approach is required.² Cine-CT represents the latest improvement in CT technology, enabling percutaneous biopsies to be performed under real-time CT imaging. This is useful for difficult biopsies (i.e., small target and limited path).

Once the image modality is determined, the patient is positioned and given a local anesthetic. Biopsies can be performed using multiple punctures, although a coaxial system is increasingly preferred. This requires initially positioning a larger gauge needle toward the tumor margin, allowing subsequent passages of a smaller needle through the larger, outer guide as many times as necessary.

Percutaneous needle biopsy is performed in close cooperation with the cytopathology department, and either a pathologist or cytopathology technician typically is present during the procedure to review the samples and assure adequacy of the

Advantages of Percutaneous Needle Biopsy

- Outpatient procedure — patient is typically home within 4 hours
- Decreased costs
- Local anesthesia or intravenous sedation, rather than general anesthesia
- Fewer complications

specimen. The majority of biopsies require that multiple samples be taken.

A small incision is made and a 19-gauge thin-wall needle is advanced through the incision and positioned adjacent to the mass. Multiple samples are obtained with a 21-gauge aspiration needle, which are examined immediately by pathology to determine if further samples must be obtained. If non representative tissue is obtained initially, the system can be redirected and the procedure repeated. Larger samples can be obtained using a 20-gauge spring-loaded biopsy gun. Samples are sent to microbiology for culture and sensitivity if a benign process is suspected. About 10 percent of needle biopsies are inconclusive or suggest false negative results and require a second procedure.³

Common Biopsy Sites

Adrenal

Adrenal biopsies are associated with a sensitivity of greater than 90 percent. Care needs to be taken in patients with suspected pheochromocytoma, who should be premedicated in order to prevent a hypertensive crisis.⁴

Bone

Due to the inherent strength of the bony cortex, bone biopsies generally are performed with boring needles. Diagnostic accuracy is greater than 80 percent and, with the exception of the vertebral body, complications are rare and limited to hemorrhage.⁵ Neurologic complications occur in up to 8 percent of vertebral body biopsies.

Liver

Percutaneous needle biopsy of the liver using ultrasound, CT and MR has greater than 90 percent sensitivity. The main complications are hemorrhage and bile leak. Hepatocellular carcinomas and various metastatic lesions may be very vascular. Hemorrhage can be life-threatening, particularly in the presence of cirrhosis and portal hypertension. Gelatin sponge particles may be used to plug the biopsy tract.⁶ A lower incidence of complications may be achieved using alternative techniques, including non directed transjugular hepatic biopsy and trans-biliary brush biopsy.

Pancreas

Percutaneous biopsy has been shown to have a sensitivity of up to 85 percent in the diagnosis of pancreatic malignancy. The main complication is the development of pancreatitis.⁷ This has been reported to occur in up to 30 percent of cases and caution needs to be taken in patients with questionable pancreatic abnormalities.

Thoracic

Percutaneous aspiration of lung, mediastinal and pleural masses is more than 90 percent sensitive for primary or metastatic carcinomas. While some physicians prefer bronchoscopy for central lesions, most thoracic masses can be safely approached percutaneously. Thoracic biopsies can be performed using either fluoroscopic or CT guidance. While fluoroscopic procedures are less expensive and typically take less time, the ability to place a needle accurately into small lesions is considerably enhanced using CT.⁸ The recent availability of CT-fluoroscopy allows for accurate placement of the needle into small lesions more quickly. A post-procedural scan should be performed to rule out pneumothorax, which occurs in up to 30 percent of patients. Smokers and former smokers are at highest risk. Patients with underlying severe dyspnea can experience significant respiratory compromise if a pneumothorax should occur, and emergent chest tube placement can prove necessary following the procedure.⁹ In the absence of pneu-

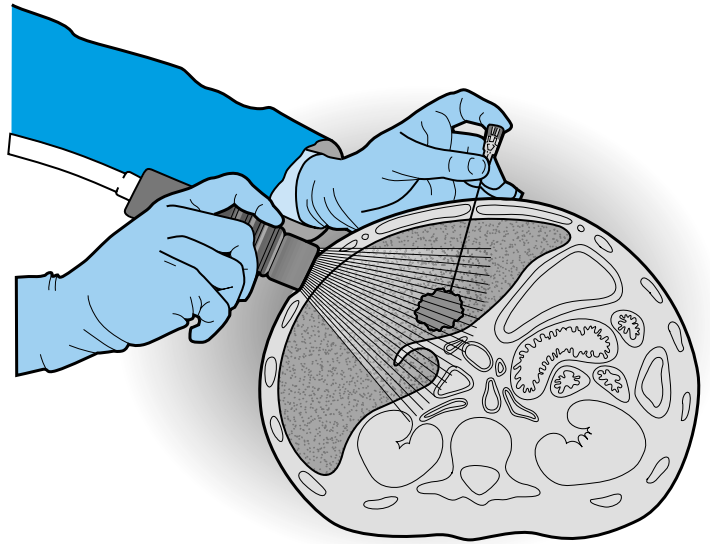


Figure 3
Percutaneous needle biopsy of a liver tumor as performed under ultrasound guidance.

mothorax, all patients should have a chest X-ray three hours after the biopsy. Other complications include pulmonary hemorrhage, which usually can be managed conservatively, and rarely, air embolism.¹⁰

Other sites

Ultrasound-guided biopsy of the kidney commonly is performed to diagnose parenchymal disease. Enlarged lymph nodes can be approached in various sites of the body and large cores are taken to analyze the architecture of the presumed lymphoma.

Sensitivity Rates of Percutaneous Needle Biopsy

Adrenal: Greater than 90 percent

Bone: Greater than 80 percent

Liver: Greater than 90 percent

Pancreas: Up to 85 percent

Thoracic: Greater than 90 percent

References:

1. Livraghi T, Damasacelli B, Lombardi C, et al. Risk in fine-needle abdominal biopsy. *J Clin Ultrasound* 1983;11:77-81.
2. Schmidt A, Kee S, Sze D, et al. Diagnostic yield of MR-guided liver biopsies compared with CT- and US-guided liver biopsies. *JVIR* 1999;10:1323-1329.
3. Teplick S, Haskin P, Kline T, et al. Percutaneous pancreaticobiliary biopsies in 173 patients using primarily ultrasound or fluoroscopic guidance. *Cardiovasc Intervent Radiol* 1988;11:26-28.
4. Koenker R, Mueller P, vanSonnenberg E. Interventional radiology of the adrenal glands. *Semin Roentgenol* 1988;22:314-322.
5. Mink J. Percutaneous bone biopsy in the patient with known or suspected osseous metastases. *Radiology* 1986;161:191-4.
6. Chuang V, Alspaugh J. Sheath needle for liver biopsy in high-risk patients. *Radiology* 1988;166:261-262.
7. Mueller P, Miketic L, Simeone J, et al. Severe acute pancreatitis after percutaneous biopsy of the pancreas. *AJR* 1988;151:493-4.
8. Westcott JL, Rao N, Colley DP. Transthoracic needle biopsy of small pulmonary nodules. *Radiology* 1997;202(1):97-103.
9. Perlmutter LM, Braun SD, Newman GE, et al. Transthoracic needle aspiration: use of a small chest tube to treat pneumothorax. *AJR* 1987;148(5):849-851.
10. Ciani P, Posin J, Shimshak R, et al. Air embolism complicating percutaneous thinneedle biopsy of lung. *Chest* 1987;92:749-751.