

Interventional Radiology GRAND ROUNDS

Topic: Preservation of Hemodialysis Access

Among the greatest challenges facing physicians and other health care professionals who care for patients with chronic renal failure is the preservation of vascular access for hemodialysis. Dysfunction or thrombosis of a vascular access is a cause of considerable morbidity, discomfort, inconvenience and cost for patients who must undergo routine hemodialysis.

Currently, there are more than 175,000 patients undergoing hemodialysis in the United States, and half or more will have at least one episode of access thrombosis each year. Approximately 20 percent to 30 percent of all hospital admissions for patients with endstage renal disease are related to complications of vascular access.¹

Access Management

Traditionally, the surgeon has been responsible for creating and maintaining the hemodialysis access. But more recently, the interventional radiologist is assuming a greater role in the diagnosis and treatment of vascular access-related problems. The majority of patients with chronic renal failure receive hemodialysis using synthetic bridge grafts made of polytetrafluoroethylene (PTFE). Because of the increased longevity and lower costs, however, a growing number of patients in the United States are using native arteriovenous fistulas as their primary vascular access.

Case History

A 58-year-old woman with chronic renal failure secondary to longstanding hypertension had been treated with hemodialysis for 18 months via a left forearm, loop configuration PTFE graft. Routine graft surveillance using the ultrasound dilution technique yielded an intragraft blood flow of 240 ml/min. The patient was referred to interventional radiology for a diagnostic fistulogram that revealed a moderate stenosis, 3 cm in length, within the venous limb of the graft (**Fig.1**). This stenosis was treated with angioplasty using a 7mm diameter balloon. Intragraft blood flow measurements, performed five days after the angioplasty procedure demonstrated that the blood flow had improved to 650 ml/min (**Fig.2**).

Figure 1
Diagnostic fistulogram of a forearm PTFE hemodialysis graft demonstrates a stenosis in the venous limb.

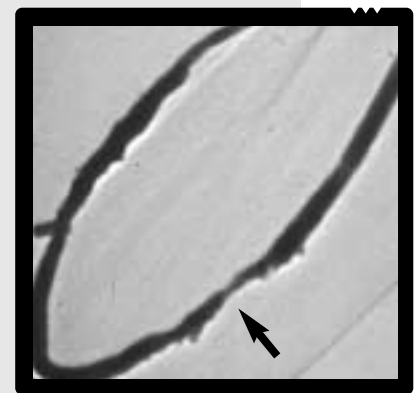



Figure 2
Following angioplasty there is resolution of the stenosis and a significant improvement in intragraft blood flow.



Prevention and Surveillance

In order to decrease the incidence of thrombosis, and other access-related complications, the Dialysis Outcomes Quality Initiative (DOQI) guidelines recommend monthly surveillance of each patient's vascular access.² A routine vascular access surveillance program, combined with early diagnosis and repair of stenoses, can decrease the incidence of vascular access thrombosis and prolong graft longevity.³ Several studies have demonstrated an increase in graft survival when elective treatment, using either endovascular or surgical techniques, is performed prior to graft thrombosis.^{3,4}

Other advantages of good surveillance include:

- reduced morbidity
- efficient, continuous, uninterrupted hemodialysis
- less need for temporary hemodialysis catheters
- fewer hospital days for access-related problems
- increased graft longevity
- reduced rate of graft replacement
- improved quality of life

Acceptable surveillance methods:

Physical examination. When a stenosis develops, a pulse can be felt in the graft up to the point of narrowing. An abnormal thrill or bruit can be detected at the site of stenosis with a diminished pulse beyond. Other physical findings may include prolonged bleeding after needle removal or swelling of the arm.

Recirculation. The amount of recirculating blood within a graft can be determined. A value greater than 15 percent suggests a developing stenosis.

Venous pressure measurements. Intra-graft pressure is measured while the patient is connected to the hemodialysis machine.

Graft blood flow. The intra-graft blood flow (ml/min) can be measured using Doppler ultrasound or the ultrasound dilution technique. The measurement of intra-graft blood flow is the most accurate surveillance method for the detection of developing stenoses.⁴

Management of Thrombosed Grafts

Despite even the best surveillance methods, graft thrombosis remains an inevitable complication of long-term hemodialysis. Until recently, most thrombosed grafts have been managed with surgical thrombectomy, but the past decade has seen a progressive increase in treatment of thrombosed grafts with percutaneous, interventional radiology techniques. Endovascular interventions performed in the radiology suite are safe, less costly and equally effective alternatives to surgical thrombectomy. Interventional radiology techniques that are used to treat dysfunctional or thrombosed hemodialysis grafts include:

- angioplasty
- intravascular stenting
- pharmacomechanical thrombolysis (i.e. pulse spray using a lytic agent)
- lyse and wait thrombolysis
- balloon thrombectomy techniques
- mechanical thrombectomy devices

No single endovascular method has been proven to be more efficacious than the others. There is evidence to suggest that the long-term patency of a hemodialysis graft is independent of the method by which the thrombus is removed, but is dependent on the successful treatment of the lesion(s) that were responsible for thrombosis. For prolonged graft patency, the key aspects of the procedure are the identification and successful treatment of all venous stenoses and the complete removal of the arterial plug.

The selection of a specific endovascular thrombectomy technique is based upon:

- graft configuration and length
- age of thrombus
- age of graft
- presence of thrombus in native veins and pseudoaneurysms
- intragraft stenoses
- cardiopulmonary status
- contraindications to lytic agents

Thrombolysis Procedure

There are four basic steps when performing a percutaneous thrombectomy of a thrombosed hemodialysis graft:

1. an initial venogram is performed to evaluate the entire native venous outflow, from the graft to the SVC. It is important to identify occlusions, high grade stenoses, and areas containing multiple, sequential stenoses
2. removal of the thrombus from the graft using an appropriate endovascular technique
3. treatment of all significant stenoses using angioplasty or vascular stents
4. dislodgement of the arterial plug

Patients who undergo a percutaneous procedure should be anti-coagulated with heparin, with dosages ranging from 3,000 to 4,000 units. In some cases, antibiotics also are administered.

Advantages of Percutaneous Interventions

There are a number of advantages to treating thrombosed hemodialysis grafts with non surgical, interventional radiology methods, including:

1. Radiological techniques are employed to thoroughly evaluate both the graft and the entire native venous outflow in the extremity.

The identification and assessment of all significant lesions is advantageous for determining the most appropriate and durable method of treatment.

2. Numerous studies have demonstrated that the initial technical success, the long-term patency, and the cost of radiologic management of a thrombosed PTFE graft are comparable to surgical thrombectomy.⁵
3. Radiological techniques preserve the patient's native veins, a critical factor in prolonging the survival of each access site.

A Team Approach

Ideally, the nephrologist, surgeon and interventional radiologist should function as a unified hemodialysis access management team. The workload of surveillance and treatment of dysfunctional or thrombosed grafts is cooperative and shared, with each individual contributing his or her expertise to provide the best long-term outcome for each patient's vascular access. Ultimately, the selection of the best approach should depend on:

- availability of a physician to expeditiously perform reparative procedures and thereby avoid the need for a temporary central venous line
- technical expertise of physicians at each institution
- patient preference

Indications for Urgent Access Treatment:

- When the patient is symptomatic with shortness of breath or chest pain secondary to fluid overload.
- When the patient presents with hyperkalemia ($K > 6.0$ mEq/L). These patients are at increased risk for cardiac arrhythmias and may require urgent hemodialysis to reduce their serum potassium level.

1. United States Renal Data System. 1997 Annual Report.
2. Schwab S, Besarab A, Beathard G, et al. NKF-DOQI Clinical Practice Guidelines for Vascular Access. National Kidney Foundation, New York 1997.
3. Sullivan KL, Besarab A. Hemodynamic screening and early percutaneous intervention reduce hemodialysis access thrombosis and increase graft longevity. *JVIR* 1997; 8:163-170.
4. May RE et al. Predictive measures of vascular access thrombosis: a prospective study. *Kid Int* 1997; 52:1656-1662.
5. Schwartz CI, McBrayer CV, Sloan JH, Meneses P, Ennis WJ. Thrombosed dialysis grafts: comparison of treatment with transluminal angioplasty and surgical revision. *Radiology* 1995;194:337-341.