

# Interventional Radiology GRAND ROUNDS

## TOPIC: Central Venous Access

Central venous access catheters (CVAC) are increasingly used for a variety of indications including hemodialysis, parenteral nutrition and the long-term administration of chemotherapeutic, antibiotic or anti-fungal agents. Central venous access can be achieved by interventional radiologists from both peripheral and central veins using a variety of techniques to insert a wide array of catheters and ports (Fig. 1). Approximately 3.4 million central venous access catheters are placed in patients, in the United States each year.

### Interventional Radiology Placement

Interventional radiology techniques in the placement of CVACs were initially developed to provide central venous access in unconventional cases in which there were no good surgical alternatives. In recent years, percutaneous placement techniques using radiologic guidance have increased, and in many institutions interventional radiology placement is the method of choice.

There are a number of advantages to placing central venous access devices in the interventional radiology suite, including higher technical success rates. The rate of successful placement with image-guided techniques approaches 100 percent<sup>1-4</sup> compared to 44 percent – 74 percent for surgical placement via cutdown of the cephalic vein,<sup>5-6</sup> and 92 percent – 100 percent for other surgical techniques.<sup>7-10</sup>

Modern angiographic materials also provide improved safety and efficacy during access to the venous system compared with historical access procedures. Small needles, guide wire and sheath use, better access devices, and the use of ultrasound or contrast-enhanced fluoroscopic guidance techniques that allow accurate visualization of the target vein, have all dramatically improved efficacy and safety by reducing the risks of inadvertent punctures of nearby arteries or the lung.<sup>3-4, 9-10</sup>

Interventional radiology techniques also allow for greater precision. With fluoroscopic guidance, the catheter tip can be directed into the optimal position within the venous system, before the procedure is terminated. By avoiding surgical cut-down techniques, which are more likely to result in sacrifice of the vein, radiologic placement preserves future access and decreases patient discomfort.

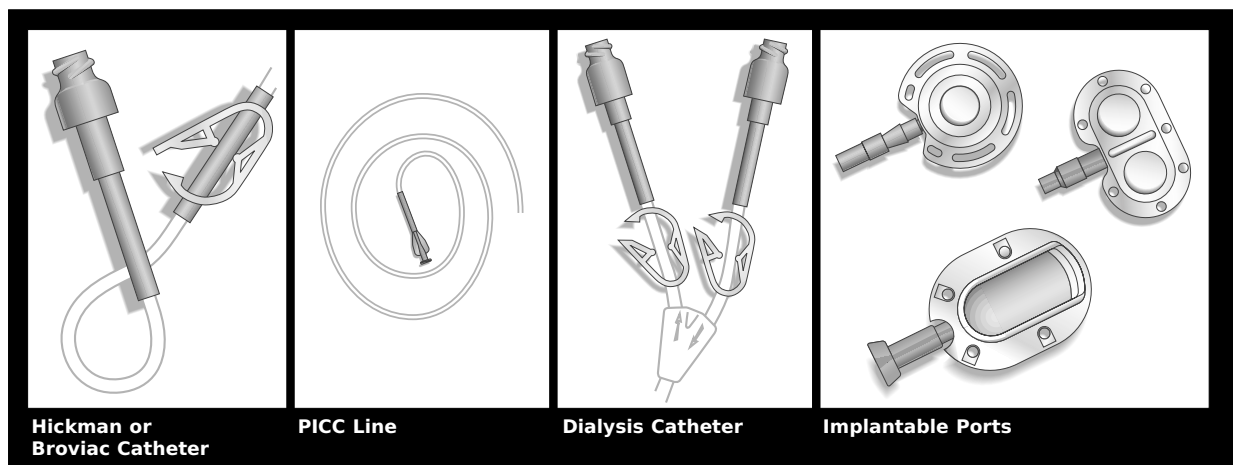
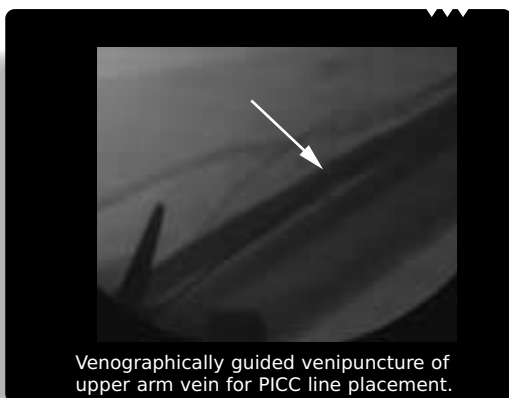
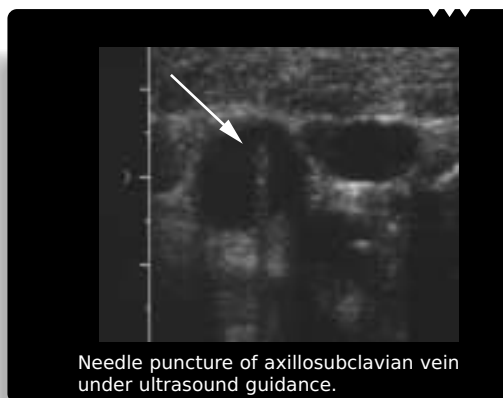
Figure 1



Venographically guided venipuncture of upper arm vein for PICC line placement.



Needle puncture of axillosubclavian vein under ultrasound guidance.

Other advantages include shortened procedure times and decreased costs. Placement in the interventional radiology suite typically requires one-third to one-half the time needed for surgical placement. The schedule in the interventional radiology suite is often more flexible than the operating room schedule, generally allowing same day service for CVAC placement. Placement of CVACs in the interventional suite is typically half the cost of placement by surgical cutdown techniques.

#### Advantages of Interventional Radiology Placement

- Higher technical success rates
- Fewer procedural complications
- More consistent catheter placement
- Shortened procedure time
- Decreased costs

#### Device Type

Consultation between the referral physician and interventional radiologist is important in selecting the appropriate central venous access device, which depends on the frequency, type, and length of therapy; the patient's level of activity; and the patient's ability to perform routine catheter care. Device types include:

- Non-tunneled catheters, which are designed for short- or intermediate-term access. These include standard triple lumen CVACs and peripherally inserted central catheters (PICC lines).
- Externally tunneled catheters that are designed for at-home or long-term use. These devices are appropriate when continuous or frequent access is required, when high flow rates are needed, as for hemodialysis or apheresis, and when patients are particularly adverse to frequent needle sticks.
- Totally implantable devices, or subcutaneous ports, which are implanted in the chest wall or upper extremity for long-term, intermittent use.

#### Methods of Placement

Percutaneous placement of catheters requires venous access, tunnel or subcutaneous pocket formation, if needed, and positioning of the catheter within the central venous system. Venous access is typically guided with contrast-enhanced fluoroscopy or ultrasound. Conventional central venous access sites include the axillosubclavian, and internal and external jugular veins. Typical peripheral venous access sites include basilic, cephalic, and brachial veins in the upper extremity. Unconventional sites include the inferior vena cava, hepatic veins, collateral veins, and occluded venous segments.

## Complications

Procedural complications related to device placement occur in less than 2 percent of patients and have been significantly minimized through the use of ultrasound and fluoroscopic guidance and the routine use of small, 21-gauge needles.<sup>1-3</sup> Late complications include catheter thrombosis, venous thrombosis and thrombophlebitis. Long-term catheter patency may be threatened by fibrin sheath encasement of the intravenous catheter tip, which impairs blood sampling and infusion. This complication may be treated with urokinase infusion or by mechanical disruption of the sheath with a guidewire or loop snare. The latter procedure is performed by interventional radiologists under fluoroscopic guidance, and can prevent the need to replace tunneled catheters or ports.<sup>11</sup> The most significant complication, regardless of method of placement, is infection which occurs in 10 percent to 30 percent of cases, or at the rate of 1.4 per 1,000 days.<sup>12,13</sup> Some infections, if detected early, can be managed with local care and antibiotics without catheter removal. Infections in the tunnel or port pocket frequently require device removal.

## Long-term Catheter Care

It is important that a member of the nursing team or other professional staff teach proper catheter care and dressing changes to prevent infection, as well as instruct the patient or care giver in access and heparinization techniques and minor catheter repair.

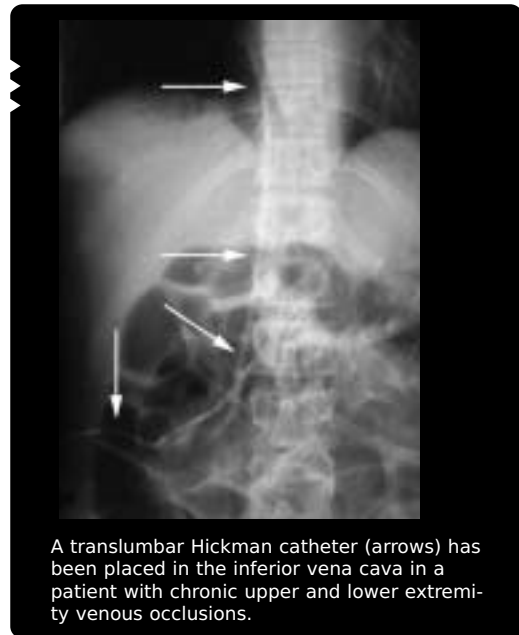## References:

1. Hull JE, Hunter CS, Luiken GA. The Groshong catheter: initial experience and early results of imaging-guided placement. *Radiology* 1992;185:803-807.
2. Openshaw KL, Picus D, Hicks ME, et al. Interventional radiologic placement of Hohn central venous catheters: results and complications in 100 consecutive patients. *Journal of*

### When Access is Limited....

In the presence of central venous occlusion, interventional radiology techniques offer a number of alternative access routes and methods, including:

- Translumbar, direct inferior vena cava
- Transhepatic, hepatic venous inferior vena cava
- Transthoracic, intercostal vein to azygous/hemizygous vein
- Recanalization of central venous occlusions
- Various upper extremity transcollaterals
- Common femoral or greater saphenous vein



*Vascular and Interventional Radiology*  
1994;5:111-115.

3. LamÇris JS, Post PJM, Zonderland HM, et al. Percutaneous placement of Hickman catheters: comparison of sonographically guided and blind techniques. *AJR Am J Roentgenol* 1990;155:1097-1099.
4. Robertson LJ, Mauro MA, Jaques PF. Radiologic placement of Hickman catheters. *Radiology* 1989;170:1007-1009.

5. Reed WP, Newman KA, deJongh C, et al. Prolonged venous access of chemotherapy by means of the Hickman catheter. *Cancer* 1983;52:1185-1192.
6. Thomas JH, MacArthur RI, Pierce GE, Hermreck AS. Hickman-Broviac catheters: indications and results *Am J Surg* 1980;140:791-796.
7. LaBerge MT, Depee G, Malviya V. A simplified technique of Hickman catheter insertion at bedside in gynecologic oncology patients. *Gynecol Oncol* 1987;26:298-304.
8. Kirkemo A, Johnston MR. Percutaneous subclavian vein placement of the Hickman catheter. *Surgery* 1982;91:349-351
9. Davis SJ, Thompson JE, Edney JA. Insertion of Hickman catheters: a comparison of cutdown and Percutaneous techniques. *Am Surg* 1984;50:673-676.
10. Abraham JL, Mullen JL: A prospective study of prolonged central venous access in leukemia. *JAMA* 1982;248:2868-2873.
11. Crain M, Mewissen M, Ostrowski G, et al. Fibrin sheath stripping for salvage of failing hemodialysis catheters: Technique and initial results. *Radiology* 1966;198:41-44.
12. Clarke DE, Raffin TA. Infectious complications of indwelling long-term central venous catheters. *Chest* 1990;97:966-972.
13. Press OW, Ramsey PG, Larson EB, et al. Hickman catheter infections in patients with malignancies. *Medicine* 1984;63:189-200.