


Multi-society Consensus Quality Improvement Guidelines for the Treatment of Lower-extremity Superficial Venous Insufficiency with Endovenous Thermal Ablation from the Society of Interventional Radiology, Cardiovascular Interventional Radiological Society of Europe, American College of Phlebology, and Canadian Interventional Radiology Association



Neil M. Khilnani, MD, Clement J. Grassi, MD, Sanjoy Kundu, MD, FRCPC, Horacio R. D'Agostino, MD, Arshad Ahmed Khan, MD, J. Kevin McGraw, MD, Donald L. Miller, MD, Steven F. Millward, MD, Robert B. Osnis, MD, Darren Postoak, MD, Cindy Kaiser Saiter, NP, Marc S. Schwartzberg, MD, Timothy L. Swan, MD, Suresh Vedantham, MD, Bret N. Wiechmann, MD, Laura Crocetti, MD, John F. Cardella, MD, and Robert J. Min, MD, for the Cardiovascular Interventional Radiological Society of Europe, American College of Phlebology, and Society of Interventional Radiology Standards of Practice Committees

J Vasc Interv Radiol 2010; 21:14–31

Abbreviations: CEAP = clinical status, etiology, anatomy, and pathophysiology [classification], CVD = chronic venous disorder, DVT = deep vein thrombosis, EVTA = endovenous thermal ablation, GSV = great saphenous vein, HL/S = high ligation and stripping, RF = radiofrequency, SSV = small saphenous vein, SF-36 = Short Form-36, SFJ = saphenofemoral junction, SPJ = saphenopopliteal junction, SVI = superficial venous insufficiency, VCSS = venous clinical severity score, VSS = venous severity score

PREAMBLE

LOWER-extremity chronic venous disorder (CVD) is a heterogeneous medical condition whose spectrum ranges from visually apparent abnormalities including varicose veins and spider telangiectasias with or without associated symptoms to severe edema, skin ulceration,

and subsequent major disability. Venous hypertension caused by incompetent valves in the superficial veins is by far the most common cause of this condition. The incompetent valves are most often found in the great saphenous vein (GSV) or small saphenous vein (SSV) or in their tributaries. Until recently, the main treatment strategy

for incompetence in these veins was to remove them. Endovenous thermal ablation (EVTA) of the saphenous veins has been used by physicians since the late 1990s as an alternative to surgical removal. This document will review the appropriate means by which the ablative techniques are to be used to maximize benefit and mini-

From Cornell Vascular (N.M.K.) and the Department of Radiology (R.J.M.), New York Presbyterian Hospital–Weill Cornell Medical Center, New York, New York; Department of Radiology (C.J.G.), Lahey Clinic Medical Center, Burlington; Department of Radiology (J.F.C.), Baystate Health System, Springfield, Massachusetts; The Vein Institute of Toronto (S.K.), Toronto; Department of Radiology (S.F.M.), University of Western Ontario, London; Department of Radiology (S.F.M.), Peterborough Regional Health Centre, Peterborough, Ontario, Canada; Department of Radiology (H.R.D.), Louisiana State University Health Sciences Center, Shreveport, Louisiana; Department of Interventional Radiology (A.A.K.), Washington Hospital Center; Department of Radiology and Radiologic Sciences (D.L.M.), Uniformed Services University of the Health Sciences; Department of Radiology (D.L.M.), National Naval

Medical Center, Bethesda, Maryland; Department of Interventional Radiology (J.K.M.), Riverside Methodist Hospital, Columbus, Ohio; RADIA (R.B.O.), Everett, Washington; Vascular and Interventional Radiology (D.P.), University of Florida; Vascular and Interventional Physicians (B.N.W.), Gainesville; Radiology Associates (C.K.S.), Pensacola; Radiology Associates of Central Florida (M.S.S.), Leesburg, Florida; Department of Radiology (T.L.S.), Marshfield Clinic, Marshfield, Wisconsin; Department of Radiology (S.V.), Mallinckrodt Institute of Radiology, Washington University School of Medicine, St. Louis, Missouri; University Division of Diagnostic Imaging/Intervention, Department of Hepatology/Liver Transplantation (L.C.), Cisanello Hospital, Pisa, Italy. Received December 18, 2008; final revision received and accepted January 5, 2009. **Address correspondence to** N.M.K., c/o Debbie Katsarelis,

3975 Fair Ridge Dr., Suite 400 N., Fairfax, VA 22033; E-mail: nmkhilna@med.cornell.edu

None of the authors have identified a conflict of interest.

This document was prepared by the standards committee of the Society of Interventional Radiology (SIR). After completion, the document was presented to the Cardiovascular and Interventional Radiological Society of Europe and American College of Phlebology, which made recommendations and offered their endorsement for this standard of practice position statement.

© SIR, 2010

DOI: 10.1016/j.jvir.2009.01.034

mize risk of complication for the patients on whom they are employed.

The membership of the Society of Interventional Radiology (SIR) Standards of Practice Committee represents experts in a broad spectrum of interventional procedures from both the private and academic sectors of medicine. Generally, Standards of Practice Committee members dedicate the vast majority of their professional time to performing interventional procedures; as such they represent a valid broad expert constituency of the subject matter under consideration for standards production.

Technical documents specifying the exact consensus and literature review methodologies as well as the institutional affiliations and professional credentials of the authors of this document are available upon request from SIR, 3975 Fair Ridge Dr., Suite 400 North, Fairfax, VA 22033.

METHODOLOGY

SIR creates its Standards of Practice documents with use of the following process. Standards documents of relevance and timeliness are conceptualized by the Standards of Practice Committee members. A recognized expert is identified to serve as the principal author, with additional authors assigned depending on the project's magnitude. An in-depth literature search is performed with use of electronic medical literature databases. A critical review of peer-reviewed articles is performed with regard to the study methodology, results, and conclusions. The qualitative weight of these articles is assembled into an evidence table, which is used to write the document such that it contains evidence-based data with respect to content, rates, and thresholds. When the evidence of literature is weak, conflicting, or contradictory, consensus for the parameter is reached by a minimum of 12 Standards of Practice Committee members with use of a modified Delphi consensus method. For the purpose of these documents, consensus is defined as 80% participant agreement on a value or parameter.

The draft document is critically reviewed by the Standards of Practice Committee members in either a telephone conference call or face-to-face meeting. The revised draft is then sent to the SIR membership for further input/criticism during a 30-day comment period. These com-

ments are discussed by the Standards of Practice Committee members and appropriate revisions are made to create the finished Standards document. Before its publication, the document is endorsed by the SIR Executive Council.

The current guidelines are written to be used in quality improvement programs to assess thermal ablation of lower-extremity superficial venous insufficiency (SVI). The most important elements of care are (i) pretreatment evaluation and patient selection, (ii) performance of the procedure, and (iii) postprocedural follow-up care. The outcome measures or indicators for these processes are indications, success rates, and complication rates. Although practicing physicians should strive to achieve perfect outcomes, in practice all physicians will fall short of ideal outcomes to a variable extent. Therefore, in addition to quality improvement case reviews conducted after individual procedural failures or complications, outcome measure thresholds should be used to assess treatment safety and efficacy in ongoing quality improvement programs. For the purpose of these guidelines, a threshold is a specific level of an indicator that, when reached or crossed, should prompt a review of departmental policies and procedures to determine causes and to implement changes, if necessary. Thresholds may vary from those listed here; for example, patient referral patterns and selection factors may dictate a different threshold value for a particular indicator at a particular institution. The value of thresholds is the establishment of a benchmark that can take into account both operator experience and complexity of the case. Therefore, setting universal thresholds is very difficult and each department is urged to adjust the thresholds as needed to higher or lower values to meet its specific quality improvement program situation.

The SIR is committed to the basic principles of outcomes-focused, evidence-based medicine. Ideally, every Standards of Practice Committee recommendation would be based on evidence derived from multiple prospective randomized trials of adequate statistical power. Unfortunately, there currently are only a limited number of small published randomized trials that evaluate EVTA in comparison with conventional surgery. That is in part because the area of endovascular venous treatment is in evolution. The majority of the reports in the literature include clinical outcomes

and proof-of-concept-type publications. In evaluating the existing publications, several major limitations are evident: (i) extreme variation in definitions of short-term efficacy and of complications; (ii) reliance on surrogate measures of treatment success instead of scientifically rigorous assessment of clinically meaningful outcomes; and (iii) absence of systematic assessment of long-term efficacy.

The SIR recognizes the potential pitfalls of developing evidence-based EVTA standards and of making recommendations regarding the use of these devices.

INTRODUCTION: EVTA OF TRUNCAL VEIN INCOMPETENCE

Throughout this document, the procedure under discussion will be referred to as EVTA for incompetent truncal (ie, saphenous) veins. This procedure is used to ablate incompetent truncal veins in patients with SVI. The underlying mechanism of this procedure is to deliver sufficient thermal energy to the wall of an incompetent vein segment to produce irreversible occlusion, fibrosis, and ultimately resorption of the vein. The currently available devices used to accomplish this have been evaluated and approved by the Food and Drug Administration of the United States and use radiofrequency (RF) or laser energy (of a variety of different wavelengths) to deliver the required thermal dose. The thermal energy is delivered by a RF catheter or a laser fiber inserted into the venous system, either by percutaneous access or by open venotomy. The procedure is generally performed on an ambulatory basis with local anesthetic and typically requires no sedation. The patients are fully ambulatory following treatment and the recovery time is short.

These guidelines are intended for use in quality improvement programs that assess EVTA to insure the standard of care expected of all physicians who perform this procedure. The processes to be monitored include (i) patient selection, (ii) performance of the procedure, and (iii) postprocedural follow-up. Assessment of outcome measures is also desirable, and these include technical success, complications, efficacy, and recurrence rates, which are assigned threshold levels based on the currently available data.

DEFINITIONS

Anatomy

Superficial veins.—The veins of the lower extremity that are superficial to the fascia surrounding the muscular compartment are considered the superficial veins. These include innumerable venous tributaries known as collecting veins, as well as the GSV and SSV and their major named tributaries (**Fig**).

Deep veins.—The deep veins are those that are found deep to the muscular fascia. These include the tibial, peroneal, popliteal, femoral, and iliac veins, as well as the intramuscular sinusoidal and perforating veins.

GSV.—An important component of the superficial venous system, the GSV begins on the dorsum of the foot and ascends along the medial aspect of the leg to ultimately drain into the femoral vein near the groin crease. This vein resides in a space deep to the superficial and superficial to the deep fascia. This location is known as the saphenous space. The word “great” replaces “greater” or “long” by international consensus (1,2; **Fig**).

SSV.—Another important superficial vein, the SSV begins on the lateral aspect of the foot and ascends up the midline of the calf. In as many as two thirds of cases, it drains into the popliteal vein, and in at least one third of cases more cephalad into the posterior thigh. The SSV also resides in the saphenous space. The word “small” replaces “lesser” or “short” by international consensus (1,2; **Fig**).

Anterior and posterior accessory GSVs.—The anterior and posterior accessory GSVs are located in the saphenous space and travel parallel and anterior or posterior to the GSV. The anterior accessory GSV is much more common (**Fig**).

Giacomini vein.—This intersaphenous Giacomini vein is a communication between the GSV and SSV. It represents a form of SSV thigh extension that connects the SSV with the posterior circumflex vein of the thigh, a posterior tributary of the proximal GSV (**Fig**).

Truncal veins.—This term “truncal veins” refers to the saphenous veins and their intrafascial straight primary tributaries (**Fig**).

Disorders

Venous reflux.—Veins contain valves that direct blood flow in one direction.

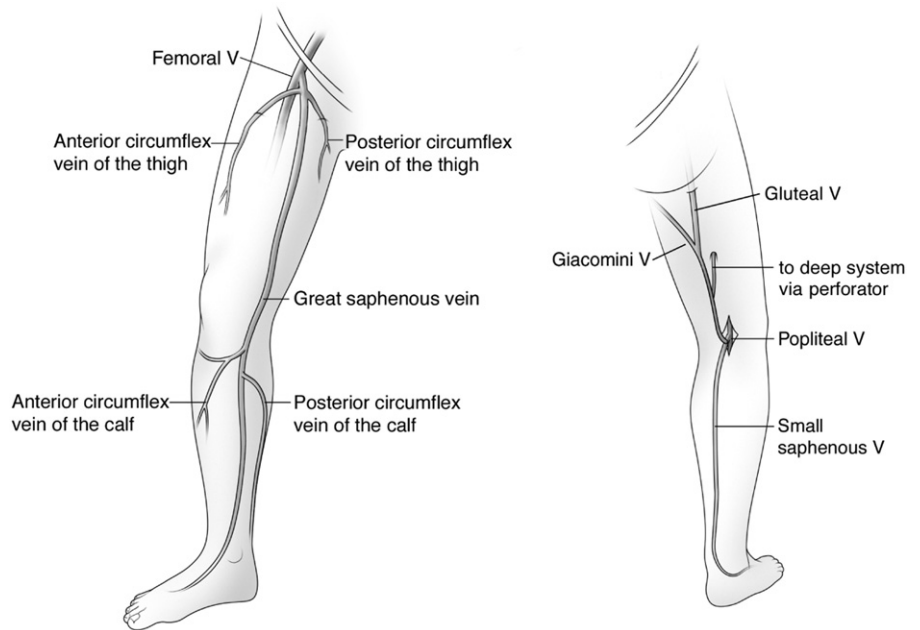


Figure. Superficial truncal veins of the lower extremity.

Usually, this is from the foot toward the heart and from the skin toward the muscles. When the valves fail, blood can flow retrogradely, and such flow is defined as reflux. Clinically significant reflux in truncal veins lasts for greater than 0.5–1.0 seconds following release of compression on the muscular mass below the vein itself.

Venous obstruction.—Obstruction of venous segments will impede venous drainage and can lead to venous hypertension. Thrombosis is the most common cause of acute venous obstruction. Such thrombosis can lead to permanent occlusion or partial or complete recanalization with or without valvular incompetence in that vascular segment.

CVD.—CVD is the clinical entity that results from chronic venous hypertension (3). The overwhelming majority of patients with stigmata of venous hypertension have primary (or idiopathic) disease of the vein wall with resultant valvular dysfunction in the superficial veins, which leads to reflux (4). This subset of CVD is known as SVI. Pathophysiologically significant reflux in the GSV or one of its primary tributaries is present in 70%–80% of patients with CVD. SSV reflux is found in 10%–20% of patients and nonsaphenous superficial reflux is identified in 10%–15% of patients (5,6). Venous obstruction, deep vein reflux, muscular pump failure, and congenital anomalies are much less

common causes. Venous obstruction is the most common of these other causes of CVD and is almost always the result of prior deep vein thrombosis (DVT). It is initially an obstructive disease but usually progresses to a combination of obstruction and superficial and deep reflux (7). Reflux or outflow vein obstruction leads to an increase in pressure in the veins. The veins themselves can dilate if unconstrained, and the pressure causes stretching of receptors in the vein wall that leads to discomfort to the patient. The pressure itself can adversely affect local tissues and metabolic processes, leading to damage in the vein wall, the skin, and subcutaneous tissues.

Neovascularization.—“Neovascularization” is a term that describes the presence of multiple small tortuous connections between the saphenous stump or the femoral vein and a residual saphenous vein or one of its patent tributaries that can occur following surgical ligation of the saphenofemoral junction (SFJ) or less commonly the saphenopopliteal junction (SPJ). This is a very common pattern of recurrence following surgical ligation of the GSV and its tributary veins near the SFJ and presents as a tangle of blood vessels in the vicinity of the SFJ (8).

Clinical status, etiology, anatomy, and pathophysiology (CEAP) classification.—“CEAP” is an acronym for a descriptive classification system that summarizes

Table 1
CEAP Classification

| Class | Description |
|-------|--|
| C0 | No visible or palpable signs of venous disease |
| C1 | Telangiectasias or reticular veins |
| C2 | Varicose veins, distinguished from reticular veins by a diameter ≥ 3 mm |
| C3 | Edema |
| C4 | Changes in skin and subcutaneous tissue |
| C4a | Eczema, pigmentation (and additionally corona phlebectasia) |
| C4b | Lipodermatosclerosis or atrophie blanche |
| C5 | Healed venous ulcer |
| C6 | Active venous ulcer |

the disease state in a given patient with CVD (4,9). The system describes the clinical status, etiology, anatomy, and pathophysiology of the problem. The clinical status scale is the most frequently used component, grading patients based on physical observations of disease severity (Table 1).

The venous severity score (VSS) is an additional means of grading the spectrum of disease severity (10). The VSS allows more detailed description of the severity of attributes of CVD compared with the CEAP system. The VSS is the sum of scores of the following clinical classification systems: Venous Clinical Severity Score (VCSS), Venous Segmental Disease Score (VSDDS), and Venous Disability Score (VDS). The VSS is an important complement to CEAP in reporting clinical success of an intervention.

Treatment Methods

EVTA.—EVTA refers to the procedure by which thermal energy is endovenously delivered to the wall of a vein with the goal of causing the veins to irreversibly occlude and ultimately fibrose. It is usually employed to eliminate incompetent superficial truncal veins responsible for the manifestations of SVI. The associated varicose tributary, reticular veins, and telangiectasias are treated separately with adjunctive therapies including microphlebectomy and compression sclerotherapy.

Sclerotherapy.—Sclerotherapy is a procedure by which a medication is in-

jected into a vein to irreversibly occlude it. This is usually done with a syringe and needle, although these medications can be injected with a catheter or intravenous cannula.

Microphlebectomy.—Also known as ambulatory or “stab” phlebectomy, microphlebectomy is a procedure by which varicose tributaries are removed with small hooks through 3–4-mm skin nicks with use of only local anesthetic.

Duplex ultrasound (US).—Duplex US is the most important imaging test to investigate patients with CVD. It uses grayscale imaging to visualize the venous anatomy and evaluate patency. Color and pulse-wave Doppler imaging is used to investigate direction and velocity of blood flow through the veins to identify reflux. Duplex US to evaluate CVD is much more complicated and time-consuming than to detect DVT, as it also involves the analysis of segmental competence as well as patency of all the deep, superficial, and perforator veins.

Tumescent anesthesia.—Tumescent anesthesia refers to the delivery of large volumes of dilute local anesthetic agent to cause a large region of anesthesia. This form of delivery typically causes a swelling, leading to the use of the term “tumescent.” Popularized by plastic surgeons, this concept has been used in the treatment of veins by delivering the anesthetic solution perivenously. For EVTA, the perivenous delivery of this solution is optimized by real-time US guidance.

Reporting Nomenclature

Anatomic success of EVTA.—Anatomic success of EVTA is defined as permanent occlusion of the entire treated vein segment. Duplex US is essential to document the anatomic success of EVTA. In the case of treatment to the SFJ, the segment of vein between the SFJ and epigastric or other large junctional vein usually remains patent. A partially occluded vein is one with reflux beyond the junction but with no reflux beyond 5 cm from that point.

Anatomic success.—Anatomic success is demonstrated on duplex US follow-up beyond 1 year. A successfully treated vein segment will either be obliterated and difficult to find or will be a thin echogenic structure on duplex US and have no flow.

Anatomic failure.—Anatomic failure

of EVTA is defined as patency with or without reflux in greater than a 5-cm segment of treated truncal vein beyond the junction or initiation of treatment point after EVTA as documented by duplex US. Anatomic failure describes situations when the vein never occludes after ablation or when it is found occluded on short-term follow-up but recanalizes at some point later.

Anatomic failure with this definition does not include reflux identified in a parallel vein such as the anterior accessory GSV after EVTA occlusion of the targeted vein. Such reflux was usually present before the EVTA or represents progression of disease. However, it is recognized anecdotally that disease progression in a parallel vein can be hastened after successful EVTA if its low-pressure outflow tributary varicosities are not eliminated. Patency of these veins may induce reflux in the parallel vein that may have been competent and previously served as the outflow vein for the varicosities before EVTA.

Recanalization.—Recanalization is defined as the process by which a previously occluded vein, documented by duplex US, regains patency. Recanalization almost always is the result of an insufficient thermal dose delivered to the vein wall.

Primary ablation.—Primary ablation denotes anatomic success after initial treatment.

Primary assisted ablation.—Primary assisted ablation denotes segmental recanalization after initial thermal ablation, resulting in anatomic success after treatment by injection of sclerosant.

Secondary ablation.—Secondary ablation denotes recanalization after initial treatment, resulting in anatomic success after treatment by a repeat procedure with the same modality.

Clinical success.—Clinical success is defined as an improvement in the clinical status of a patient as defined by one of the objective assessment instruments, such as the CEAP or VSS classification, by at least one grade. In practice, most patients treated with EVTA will also be treated with adjunctive microphlebectomy or compression sclerotherapy. It is generally believed that clinical success will be dependent on the thoroughness of the adjunctive procedures that are performed, as well as the success of the EVTA. Therefore, for the purpose of defining success, most clinical reviews use anatomic success of EVTA.

Complications

Paresthesia and dysesthesia.—Paresthesia and dysesthesia describe the loss or aberration, respectively, of normal sensory perception. Injury to the saphenous or sural nerves adjacent to the GSV or SSV, respectively, can lead to these sensory disturbances.

DVT.—DVT is thrombosis in the veins deep to the muscular fascia.

Superficial thrombophlebitis.—Superficial thrombophlebitis refers to thrombosis in veins superficial to the muscular fascia. The veins involved could include the saphenous veins and their named tributaries, as well as subcutaneous collecting veins.

Arteriovenous fistula.—An abnormal connection directly between an artery and a vein is an arteriovenous fistula. Such a connection may be created iatrogenically by a penetrating or thermal injury during EVTA.

Toxicity related to tumescent anesthesia.—Toxicity can develop from the use of large doses of lidocaine used for perivenous anesthesia.

Skin burn.—Thermal injury to the skin can occur from extension of the heat delivered into the vein.

PHYSICIAN QUALIFICATIONS

All patients with CVD should undergo a complete clinical and duplex US evaluation before being considered a candidate for EVTA. This evaluation and subsequent treatment should be performed by a physician who is appropriately trained in the care of patients with venous disorders. The body of knowledge required by such a physician includes a thorough understanding of the anatomy, physiology, pathophysiology, and clinical course pertaining to these conditions. The physician should be experienced in the performance and interpretation of duplex US of the venous system as well as conservative, medical, and procedural approaches for treating venous disorders. The requisite knowledge, clinical, and procedural experience required to care for patients with venous disorders can be acquired in a number of ways. Many physicians will acquire the necessary knowledge and skills through continuing medical education and/or mentored clinical experiences (11) after their postgraduate medical training. The knowledge and skills can also be obtained through postgraduate medical training in an Accred-

itation Council for Graduate Medical Education–recognized (or approved) postgraduate training program.

PRETREATMENT ASSESSMENT

Evaluation of the patient before treatment in an outpatient setting provides the physician an opportunity to review the patient's medical history, perform a physical examination, and evaluate the patient's venous system with Duplex US. Only after such an examination can the patient and physician engage in a conversation regarding treatment options. Patients with duplex US–documented truncal incompetence have the option of selecting conservative treatment of their symptoms with graduated compression stockings, EVTA, surgical removal of the vein, or sclerotherapy.

A complete medical history of the presenting venous problem, previous therapy and response, history of thrombosis, comorbidities, medications, allergies, and any pertinent family history should be obtained from the patient. Chronic venous insufficiency causes symptoms in many patients that can impact their quality of life (QOL). These symptoms are summarized in **Table 2**.

All these symptoms are worse with prolonged standing or sitting, improve with ambulation, and are most noticeable at the end of the day. In longstanding cases, patients may develop skin damage in the form of eczema, corona phlebectasia, pigmentation, and lipodermatosclerosis, and eventually may form skin ulceration. A family history searching for a risk of a hypercoagulable state should also be obtained. Laboratory evaluation is recommended for patients with a history strongly suggestive of a hypercoagulable state.

A complete physical examination of the patient below the waist should be performed. This should generally be performed in the standing position and should include all aspects of the lower extremities as well as the lower abdomen and pelvis in patients in whom iliac vein occlusion is suggested.

Visible vein abnormalities including telangiectasias, venulectasias, and varicose veins should be documented. Edema of the extremities should be identified. Careful attention should be directed at the skin near the ankle, as this region is most vulnerable to the effects of long-term venous hypertension.

Table 2
Leg Symptoms Associated with Chronic Venous Insufficiency

| |
|--------------------------------|
| Aching |
| Throbbing |
| Heaviness |
| Fatigue |
| Pruritus |
| Night cramps |
| Restlessness |
| Generalized pain or discomfort |
| Swelling |

Manifestations of CVD such as skin hyperpigmentation, corona phlebectasia, eczema, lipodermatosclerosis, and ulceration should be noted. It is suggested that a standardized means of clinically assessing the severity of the effects of the chronic venous hypertension, such as the CEAP scale, be used to document one's findings. In addition, it is suggested that a written documentation of the history and clinical and duplex US examination findings be produced for each patient, including a discussion of the impression and clinical recommendations. Photographs of the visible findings are also helpful to document the severity and extent of the disease.

Duplex US Evaluation

Duplex US is essential in all patients with CEAP clinical class C2 or higher CVD to identify reflux and patency and establish the pattern of disease to plan treatment. The technique of duplex US for CVD is different than for the evaluation of lower-extremity thrombosis. The goals, objectives, and technique of this examination have been reviewed in a consensus statement by the Union Internationale de Phlebologie and the American College of Phlebology, as well as in several recent publications (13–15). During this examination it is important to evaluate the anatomy and the physiology of both the superficial and deep venous systems. A thorough knowledge of the anatomy of the superficial venous system and its common variants is necessary. Accurate use of the newly accepted nomenclature to describe these veins is essential for medical reporting (1,2,16).

The aim of duplex US is to define all the incompetent pathways and their sources, which involve saphenous and nonsaphenous veins, perforating veins,

and deep veins. The evaluation should also include an assessment of the patency of the femoral and popliteal veins.

The necessary equipment includes grayscale US and pulse-wave Doppler imaging using frequencies of 7.5–10 Mhz, although higher and lower frequencies may be used depending on the patient's morphology. Color Doppler imaging is very useful and readily available as a package with most duplex US units.

Duplex US should be performed in the standing position and the examiner should thoroughly evaluate the GSV, SSV, their named tributaries, and the deep veins for both reflux and obstruction. Venous reflux is diagnosed when there is reversal of flow from the expected physiologic direction for more than 0.5 seconds following a provocative maneuver to create physiologic flow. These include calf or foot compression by the examiner, dorsiflexion by the patient, or a Valsalva maneuver to assess for competency of the SFJ. A standardized report should be created and used to describe the findings for each examination. The use of diagrams significantly enhances the dissemination of important clinical findings.

In a few clinical situations, patients may require further imaging to characterize venous obstruction, reflux, or venous anomaly in the pelvis or lower extremity such as conventional ascending, computed tomographic (CT), or magnetic resonance venography. Rarely patients require a conventional catheter, CT, or MR arteriogram to evaluate for the possibility of an arteriovenous malformation. Following clinical and imaging evaluation, the patient's clinical state should be summarized as to the severity, cause, anatomic location and pathophysiology using the CEAP classification system.

Indications for EVTA

Patients seeking treatment of CVD can be divided into those in whom it is medically indicated and those in whom it is restorative (ie, cosmetic). The great majority of patients with CEAP class C2 or higher CVD have symptoms, and treatment is medically indicated to improve QOL. For a smaller subset of patients, derangements in the health of the skin in the vulnerable medial ankle and calf regions will represent medical indications for treatment.

Table 3
Medical Indications for EVTA

| | |
|---|--|
| Clinical | |
| Quality of life affecting symptoms of venous insufficiency (see Table 2) | |
| Skin changes associated with chronic venous hypertension | |
| Corona phlebectasia | |
| Lipodermatosclerosis | |
| Atrophie blanche pigmentation in the gaiter region of the lower leg | |
| Healed or active ulceration | |
| Edema | |
| Superficial thrombophlebitis | |
| Anatomic | |
| Significant duplex US–documented reflux | |
| Straight vein segment | |
| Intra- or epifascial vein segment meeting other anatomic criteria | |

It is generally believed that reflux in truncal veins must be treated before addressing any visible abnormalities. However, there is some debate whether some forms of minor or segmental truncal reflux may be left untreated, in which case treatment of only the abnormal tributaries can be safely and durably undertaken.

EVTA is a treatment option for eliminating reflux in a straight superficial venous segment. The indications for ablation of incompetent truncal veins are identical to those for surgical phlebectomy of a given incompetent vein ([Table 3](#)). These include reflux in a truncal vein of duration greater than 0.5 seconds that is responsible for the patient's symptoms, skin findings, or cosmetic abnormality. Treatment of competent vein segments below an incompetent vein segment, such as the below-knee GSV when only the above-knee GSV is incompetent, is not substantiated by data and should be discouraged to avoid unnecessary complications. EVTA can be applied to any sufficiently straight incompetent truncal or superficial vein that would allow passage of the device.

Treatment of short segments of truncal incompetence is justified but may be made more challenging by securing sufficient access of the vein to allow treatment. Data to evaluate the success of short segment treatment are not available. Care should be taken to identify other segments of incompetence in the treated vein or in other veins in the same extremity as complete obliteration of such reflux is more likely to result in durable elimination of the presenting problem. This includes searching for refluxing remnants of veins previously

treated with surgery, sclerotherapy, or EVTA.

Treatment of incompetent superficial truncal veins in the setting of deep vein reflux is safe. In many cases the reflux in the deep veins is related to overload of the deep system by the by the regurgitant fraction or related to a siphon effect of the incompetent trunks (12). In these cases, elimination of superficial reflux is likely to reverse the deep reflux (17).

Treatment of incompetent superficial truncal veins in the setting of deep vein obstruction requires a careful assessment of the adequacy of the patent segment of the deep venous system. If the deep system is adequate and the superficial venous incompetence is leading to CEAP class C5 or C6 CVD, EVTA of the causative veins is justified. Treatment of competent but enlarged superficial venous segments has no proven medical benefit and should not be performed. In some cases the enlarged vein may ultimately become incompetent. In other patients, the enlarged vein may be functioning as a reentry or collateral pathway for another source of reflux or deep vein obstruction.

The use of EVTA to close incompetent perforating veins has been described. At this point, the indications and contraindications for use as well as the success rates and safety of this approach have only recently begun to be evaluated (18). The use of EVTA to directly close surface varicose veins is not encouraged. These veins are usually too tortuous for current generation devices to pass through. Also, these veins are very superficial; EVTA of such veins carries a high risk of thermal skin injury (19).

Table 4
Relative Contraindications for EVTA

| |
|--|
| Pregnancy or nursing* Obstructed deep venous system inadequate to support venous return after EVTA Liver dysfunction or local anesthetic allergy limiting local anesthetic agent use Severe uncorrectable coagulopathy, intrinsic or iatrogenic Severe hypercoagulability syndromes Inability to wear compression stockings secondary to inadequate arterial circulation, hypersensitivity to the compressive materials, or musculoskeletal or neurologic limitations to donning the stocking itself Inability to adequately ambulate after the procedure Sciatic vein reflux Nerve stimulator |
|--|

* Secondary to concerns related to anesthetic drug use and related to vein or heated blood effluent which may pass through the placenta to the fetus.

Contraindications for EVTA

The absolute contraindications for EVTA have yet to be completely defined. Relative contraindications include several features, some of which relate to the clinical condition of the patient and others to the anatomy (Table 4).

In general, very few truncal veins are too close to the skin to prevent EVTA. Even in thin patients, these veins can be pushed away from the skin with tumescent anesthesia. Some believe EVTA of an extrafascial vein such as the superficial accessory GSV may lead to a higher incidence of skin pigmentation and skin puckering, and encourage phlebectomy over EVTA of this vein. No data exist to evaluate the incidence of these observations, but anecdotally these side effects almost always seem to be transient.

Large-diameter veins are safely and effectively treated with EVTA assuming sufficient tumescent anesthetic solution is infiltrated around the vein to collapse it. At this point there are no data to suggest a correlation between diameter and anatomic success of or complications after EVTA. Aneurysmal dilation of the proximal GSV or SSV at their respective junctions is proposed by some as a contraindication as it is a possible risk factor for thrombus extension into the deep venous system. This concern has yet to be substantiated by data. Avoidance of treating incompetent sciatic veins with EVTA is suggested given this vein's intimate proximity to the sciatic nerve, and the potential for thermal motor and sensory nerve damage.

The liver metabolizes the anesthetic agents commonly used with EVTA. Patients with impaired liver function may be at risk for anesthetic toxicity. In these

patients, the use of appropriate general or regional analgesia coupled with saline tumescent infiltration may be a way to allow safe EVTA. Cold saline solution has been demonstrated in a small series as an alternative tumescent agent with similar efficacy to dilute lidocaine (20).

Post-EVTA ambulation and the use of graduated compression hose is important following venous treatment to minimize the risk of postprocedural DVT and to decrease superficial thrombophlebitis in dependent tributary (ie, surface) varicose veins. This common belief has not been substantiated by data. However, at this point, based on this prevailing notion, those patients with vascular, cutaneous, neurologic, or musculoskeletal conditions that make ambulation or the use of compression stocking difficult should be carefully screened for the need to perform EVTA.

Complications after EVTA may be potentiated by native and iatrogenic coagulopathies. There are few data with regard to these issues other than extrapolation from literature regarding safety with other venous procedures (21). EVTA performed on patients taking aspirin or nonsteroidal antiinflammatory medications seems to be safe. No data on the safety and efficacy of EVTA in patients being treated with platelet aggregation inhibitors such as clopidogrel are available. Anecdotal reports suggest that EVTA is safe in patients receiving this therapy. In patients in whom it is safe to stop such therapy, the drugs probably should be discontinued for at least 10 days to minimize bleeding complications as in other venous procedures (21). The safety of EVTA used on patients being treated with warfarin was

evaluated in a single small prospective cohort study (22). In this review, 48 patients with GSV reflux were treated with an 810-nm laser with 12W with roughly 60 J/cm. Twenty-four patients were on warfarin and a matched cohort of 24 patients not on warfarin were selected as a control group. The INR of the warfarin treated patients was 2.3–4.1. There were no significant bleeding complications or excessive bruising in either group following EVTA. There was a tendency toward less effective ablation at one-year follow-up with DUS in the anticoagulated group but given the sample size this was not statistically significant. Of note, the energies in the failed ablations were in the 44–62 J/cm range. Low molecular weight heparins are routinely used at prophylactic doses in Europe immediately following EVTA with little risk of bleeding (23). However, there are no data that evaluate the safety of EVTA during heparin therapy or for its use immediately after EVTA at therapeutic doses.

EVTA in patients with hypercoagulable states in theory may lead to an increased incidence of DVT (23). Patients with established clotting risks should be carefully screened for the need to perform EVTA. In those who require therapy for significant QOL-related symptoms or morbidity from CEAP class 4–6 chronic venous insufficiency, periprocedural anticoagulation may be considered. However, indications for use, recommendations of drug choice and therapy duration, and the efficacy of such prophylaxis have not been evaluated.

EVTA with RF ablation using the first generation devices uses a monoterminial circuit and a bipolar electrode design. As a result, electromagnetic interference with cardiac pacemakers or implantable defibrillators is very unlikely (24). The original Food and Drug Administration approval for the device included the presence of a cardiac pacemaker or implantable defibrillators as a contraindication. The Food and Drug Administration has since removed this restriction, although the manufacturer recommends "appropriate precautions" be used. There are no concerns of pacemaker or defibrillator interference with the new RF catheter called Closure Fast.

First generation RF ablation use in patients with spinal cord, dorsal column, transcutaneous nerve, or vagal nerve stimulators may lead to a dys-

function in these devices. Consultation with an appropriate physician about the safety of RF ablation would be necessary in patients with such stimulators. There are no concerns about interference with these devices with the use of Closure Fast.

EVTA PROCEDURE

EVTA begins with a DUS evaluation by the treating physician to confirm the location and extent of the venous insufficiency and to direct skin marking of the vein segment or segments to be treated. The evaluation and skin marking is an essential part of the EVTA procedure and it is incumbent on the physician performing the procedure to be as accurate as possible to ensure an adequate and durable outcome. The important components of the pre-EVTA DUS include identifying the correct vein or vein segments to be treated (including determining the length of vein or veins that are incompetent to ensure complete treatment), and to mark on the skin their course along with other important anatomical landmarks. These important anatomic landmarks include deep vein junctions; hypoplastic, aplastic, aneurysmal, or tortuous segments; refluxing perforating veins communicating with the vein to be treated; and large tributaries. Informed consent, including a thorough discussion of risk, benefits, and alternatives, should be obtained from the patient. The patient should then be appropriately positioned on a table to allow access to all areas that are to be treated. The region to be treated is then sterilely prepared and isolated with sterile barriers. The physician performing the procedure should wear sterile gloves and a gown, and eye protection (including laser-specific attenuating glasses for the operator, patient, and staff in the room when appropriate), and all health care providers involved should follow universal precautions. A US-guided venous access into the lowest incompetent segment of the vein is then performed. In some cases several US-guided venous access sites may be needed if the vein to be treated is discontinuous because of prior treatment or phlebitis; or if the veins have aplastic, hypoplastic, or tortuous vein segments; or if vein spasm prevents advancement of the ablation device or sheath. Cases requiring ablation of more than one incompetent vein will also re-

quire multiple entry sites. Open venotomy requiring a small skin incision may also be used to introduce an EVTA device. Once venous access is achieved, a guide wire is passed intravenously and a vascular introducer sheath (or sheaths) is inserted.

There are no data to suggest improved disease-free durability or clinical improvement for treatment of normal vein segments below documented incompetent GSV or SSV segments. However, the access site or sites for EVTA should allow treatment of the entire incompetent segment or segments if two or more segments of the same truncal vein are involved. This may include ablation of intervening normal segments. Venous access(es) is then followed in most cases by positioning the ablation device or devices to be used to the most central location of vein to be treated. The positioning of the device should be carefully monitored by duplex US to ensure the device is intravenous, that the device allows access to the entire incompetent venous segment, and that the working end is not positioned in the deep venous system. Accurate demonstration of the device and its positioning in the venous system require meticulous DUS technique and should be performed by a skilled operator. The operating physician usually performs the DUS during EVTA. The physician may delegate the performance of the DUS to an appropriately trained individual, although the responsibility for accurate final positioning rests with the treating physician.

To treat reflux of the GSV beginning at the SFJ, the device is generally positioned just below the junction of a competent epigastric vein, or other junctional branch to be spared, unless otherwise indicated. Segmental treatment of the GSV or of GSV remnants after previous surgery or ablation may also be appropriate.

For SSV ablation, the tip of the device is positioned just beyond the take-off point of a competent thigh extension of the SSV or gastrocnemius vein, whichever is more peripheral. If neither of these veins has an SSV connection, ablation generally begins at the cephalad end of the intr fascial SSV before it passes below the muscular fascia. If the thigh extension of the SSV is also incompetent, this segment may be treated along with the SSV.

Treatment of the anterior accessory GSV, superficial saphenous vein, and

other tributary veins is also appropriate as long as they are straight enough to traverse with the EVTA device and if an appropriate amount of tumescent anesthetic is used to protect the skin from a thermal injury. Once the device is appropriately placed for ablation, the patient is placed in Trendelenburg position to facilitate vein emptying and perivenous tumescent anesthesia is then delivered. Optimal delivery of this fluid into the saphenous space is accomplished with real-time duplex US guidance. The purposes of the tumescent fluid are to externally compress and empty the vein to improve thermal transfer to the vein wall and to separate the vein from surrounding structures, as well as for its anesthetic effect.

The thermal energy is then delivered using protocols inherent to each device; data related to success based on the delivered thermal dose for EVTA will be discussed later. Aspirating on the sheath or external compression of the skin over the tip of the ablation catheter during thermal delivery has been performed by some in an attempt to further empty the vein and to contain any heated blood from the deep vein beyond the junction. This may have some benefit near the junctional end of a large vein but has not been evaluated. The use of cold tumescent anesthetic agent has also been anecdotally suggested as helpful in inducing vein spasm to assist in vein emptying and energy transfer in large veins.

Manual compression is applied to the vein entry site to gain hemostasis after device removal. After the procedure, the patient is placed in a graduated compression stocking for 1–2 weeks (an additional compressive dressing is often used for the first few days if phlebectomy is performed concurrently). Ambulation is initiated immediately and encouraged following the procedure, although the value of these practices has not been established scientifically.

The tributary varicose veins improve or less commonly disappear in a reasonable number of patients following EVTA (25,26). However, most patients require adjunctive procedures to eliminate the varicose tributaries. Their eradication is believed important to complete the hemodynamic correction and maximize symptomatic improvement, eliminate incompetent reservoirs that could facilitate the development of new incompetent path-

ways, and complete the cosmetic improvement of the treated limb. Also, as a result, their elimination may improve the success of EVTA and possibly slow the progression of venous disease in parallel venous trunks. Superficial thrombophlebitis of large incompetent tributaries occurs following ablation of the underlying reflux without phlebectomy. It has been proposed that concurrent phlebectomy of such veins may reduce the incidence of this minor complication. At this point, data to substantiate these thoughts are not available.

POSTPROCEDURAL FOLLOW-UP CARE

Immediately following EVTA, patients are instructed to ambulate regularly. Vigorous exercise is generally discouraged for the first week after EVTA to avoid producing increased venous pressure near the central, junctional end of treated vein segments, although there are no data to substantiate this recommendation. Long periods of immobility such as those that occur with long air flights or car rides soon after EVTA likely should be discouraged to minimize venous stasis that could increase the risk of DVT. These practices are not based on data.

There are no convincing data to support the routine use of anticoagulants with EVTA. In Europe the use of a short course of postprocedural prophylactic-dose low molecular weight heparin is common (23). The complication rate following its use does not seem substantially increased, but this has not been directly investigated. Similarly, there are no data to clinically evaluate the of these practices in enhancing treatment efficacy, preventing complications such as deep or superficial vein thrombosis, or potentially increasing the rate of postprocedural bleeding complications.

Patients should return for periodic clinical and duplex US evaluation to confirm vein closure and exclude complications. If a physician were attempting to identify thrombus extension across the SPJ or SFJ, duplex US in the first 72 hours after EVTA seems to be necessary (27). There is no evidence as to the best time to evaluate for DVT in the crural, femoral, or popliteal veins. However, given the transient and benign clinical course of EVTA heat-induced thrombus extension in the deep veins at the junctions as well as in the

deep veins of the calf, the necessity of evaluating all patients early for thrombus cannot be substantiated.

Follow-up duplex US examinations should be periodically performed to evaluate the anatomic success of EVTA. The natural history of a successfully treated truncal vein includes acute vein wall thickening without significant intraluminal thrombus in the first few weeks after treatment. This is followed over the next few months by progressive vein shrinkage and eventual disappearance on US examination (15,28,29). Follow-up duplex US will no longer be needed when the treated vein is no longer visible. Periodic follow-up duplex US may be needed to evaluate the etiology of any new tributary varicosities to determine whether they are related to a recurrence of reflux in the treated truncal vein or progression of disease in a different venous pathway.

CLINICAL EVALUATIONS OF EVTA

For RF ablation, proof-of-concept studies including multiple case series and a large sponsor-organized registry form the bulk of the published experience reporting success and complications with this procedure. The data included in this review were derived from the published experience with the first generation RF devices (Closure and Closure Plus). Recently, a modified version of RF catheter, Closure Fast, has been approved for use in the US. The limited data that were available at the time this manuscript was being prepared is also included (43) (Table 5).

For laser ablation, multiple proof-of-concept and case series have been published reporting success and complications with this procedure using lasers with multiple different wavelengths (Table 6) (23,28–64).

Suggested action thresholds for anatomic success are presented in Table 7. In addition, clinical outcomes investigation of RF ablation or laser ablation include several small randomized controlled trials comparing each procedure with conventional vein stripping (Table 8).

SUCCESS RATES

Observation Data Regarding Anatomic and Clinical Success

Anatomic success rates with RF ablation and laser EVTA of the GSV have

generally been reported between 85% and 100%. The follow-up for these evaluations varies from 3 months to 4 years. There are fewer data for the SSV but the published results are qualitatively similar.

Most EVTA recanalizations occur in the first 6 months, and all occurred in the first 12 months following EVTA in every reported series. This has been interpreted as suggesting recanalization may be related to insufficient thermal energy delivery to the target vein. With EVTA, in most cases the first 1–2 cm of the treated vein beyond the SFJ or SPJ remains patent. Post-EVTA patency of segments less than 5 cm long beyond the junction are the most common form of failure. Posttreatment patency of more than 5 cm of treated vein segment is much less common (37). Less successful closure of the proximal vein segment may be related to an increased likelihood of insufficient thermal transfer to this portion that is generally of larger caliber, more difficult to empty, and less likely to develop spasm during tumescent anesthetic administration. As a result, it is less likely to develop good device and vein wall apposition in this segment, which is thought important for optimal vein wall energy deposition to achieve successful laser or RF ablation.

There is a correlation between the amount of thermal energy delivered and the success of laser EVTA.

With laser, energy deposition has been described as that deposited per centimeter of vein length (J/cm) or as that deposited to the vein wall using a cylindrical approximation of the inner surface area of the vein (J/cm²), which can be considered a fluence equivalent (54). Durable vein occlusion was demonstrated in an observational series (51) as more likely when the energy delivered exceeded 80 J/cm, with a median observation of 30 weeks. Early occlusion was also demonstrated as also more likely in a different nonrandomized study (54) that compared two different energy levels. In this study, a statistically significantly higher occlusion rate by duplex US at 3 months was seen with mean fluence levels of approximately 30 J/cm² (60 J/cm) compared with fluence rates of 12 J/cm² (24 J/cm). High rates of vein occlusion and ultimate duplex US disappearance was noted in a series in which the thermal dose in each segment of the GSV was tailored to the

Table 5
Published Observational Series of RF Ablation for Truncal Reflux (28,30–44)

| Study, Year | Limbs | Vein | Anatomic Success (%) | Duplex US Follow-up (mo) | Major Complications (%) |
|-----------------------------|---------|---------|----------------------|--------------------------|-------------------------|
| Goldman et al, 2000 (30) | 12 | GSV | 100 | 6 | 0 |
| Goldman et al, 2002 (31) | 41 | GSV | 68 | 6–24 | 0 |
| Weiss et al, 2002 (32) | 98 | GSV | 96 | 6 | 1 |
| Merchant et al, 2002 (33) | 21 | GSV | 90 | 24 | NR |
| | 223 | GSV | 87 | — | 6 |
| | 232 | GSV | 84 | 12 | NR |
| | 142 | GSV | 85 | 24 | NR |
| Wagner et al, 2004 (34) | 28 | GSV | 95 | 3 | 3 |
| Pichot et al, 2004 (28) | 63 | GSV | 90 | 25 | NR |
| Hingorani et al, 2004 (35) | 66 | GSV | — | — | 16 (DVT) |
| Merchant et al, 2005 (36)‡ | 1161/61 | GSV/SSV | — | — | — |
| | 473 | — | 87 | 12 | NR |
| | 263 | — | 88 | 24 | NR |
| | 133 | — | 84 | 36 | NR |
| | 119 | — | 85 | 48 | NR |
| | 117 | — | 87 | 60 | NR |
| Nicolini et al, 2005 (37) | 68 | GSV | 88 | 36 | 0 |
| Merchant et al, 2005 (38) | 98 | GSV | 89 | 48 | NR |
| Mozes et al, 2005 (39) | 56 | GSV | NR | NR | 8 |
| Puggioni et al, 2005 (40)‡ | 53 | GSV/SSV | 91 | 1 | NR |
| Dunn et al, 2006 (41) | 85 | GSV | 90 | 6 | NR |
| Ravi et al, 2006 (42) | 159 | GSV | 97 | 36 | NR |
| Almeida et al, 2006 (43)‡ | 95/11 | GSV/SSV | 95 | 16† | 0 |
| Proebstle et al, 2008 (44)* | 252 | GSV | 99 | 6 | 0 |

Note.—Clinical evaluations of laser ablation have been performed using laser energy of several wavelengths (810, 940, 980, 1,329, and 1,320 nm) that are produced by several manufacturers. The published experience with this technique is composed of proof-of-concept studies including multiple cases series (Table 6). NR = not reported.

* Study used the ClosureFast device.

† Mean measurement.

‡ The data for GSV and SSV were reported together in this review.

diameter in that segment (64). The ranges of energies used included 50 J/cm for veins 4.5 mm or smaller and 120 J/cm for veins larger than 10 mm in diameter. No increase in complications was seen with any of the higher-energy strategies. At this point, a prospective randomized evaluation of the relationship of the amount of laser energy deposition at a fixed wavelength and its effects on the rate of anatomically successful vein obliteration and complication rates has not been performed.

A similar correlation between the energy delivered and success has been defined for RF ablation (36). When pullback rates were decreased from 3 cm/min to 2 cm/min, a clear correlation with anatomic success was demonstrated. Most of the clinical data collected for RF ablation use a target treatment temperature of 85°C and a pullback rate of 3 cm/min. Equivalent results with observational studies at 6 months have been demonstrated with

the use a target temperature of 90°C in combination with a faster catheter pullback rate (41). This has allowed energy delivery times to be shortened by 50% without an increase in complications.

Patients with a high body mass index have been shown to have a higher rate of failure with laser and RF ablation (36,56). The rationale for this observation is unclear, although it is known that obese patients have higher central venous pressures and a higher frequency of chronic venous disease.

Successfully treated veins have been demonstrated to occlude and shrink with time (28,29,64). Successfully treated veins eventually shrink and become difficult to find. The average mean duration for a treated GSV to shrink to a fibrous cord of less than 2.5 mm diameter is 6 months (29). In another study, at 1 year following laser ablation of the GSV, the treated segments were not visualized in 95%, occluded but visible in 2%, and patent in

2% (62). In another study (65), at 2-year follow-up, 41% of occluded veins were undetectable and 51% had shrunk to a mean diameter of 2.9 mm.

Late clinical recurrence is extremely unlikely in an occluded vein that has shrunken to a noncompressible cord (28,37,64). Based on this and surgical data that demonstrate that the pathologic events that lead to recurrence usually take place within 2 years (66), later clinical recurrences are more likely related to development of incompetence in untreated veins or vein segments (ie, progression of disease in other veins). To a great extent, late clinical success after EVTA is predicated by the natural history of the venous insufficiency in a given patient, the ability of the treating physician to identify and eliminate all incompetent pathways (often described as tactical and technical success), as well as the success of the adjunctive procedures used to eradicate any coexistent incompetent tributary veins after EVTA.

Table 6
Published Observational Series of Laser Ablation for Truncal Reflux (23,29,40,42,43,45–64)

| Study, Year | Limbs | Vein | Anatomic Success (%) | Duplex US Follow-up (mo) | Major Complication Rate (%) |
|-------------------------------|---------|---------|----------------------|--------------------------|-----------------------------|
| Navarro et al, 2001 (45) | 40 | GSV | 100 | 4.2 | 0 |
| Min et al, 2001 (46) | 90 | GSV | 97 | 9 | 0 |
| Proebstle et al, 2003 (23) | 104 | GSV | 90 | 12 | NR |
| Oh et al, 2003 (47) | 15 | GSV | 100 | 3 | NR |
| Min et al, 2003 (48) | 499 | GSV | 98 | 17 | 0 |
| Proebstle et al, 2003 (49) | 39 | SSV | 100 | 6 | NR |
| Perkowski et al, 2004 (50) | 154 | GSV | 97 | 6–18 | NR |
| | 37 | SSV | 96 | 6–18 | NR |
| Sadick et al, 2004 (51) | 31 | GSV | 97 | 24 | 0 |
| Timperman 2004 et al, (52) | 111 | GSV | NR | 7 | NR |
| Proebstle et al, 2004 (53) | 106 | GSV | 90 | 3 | NR |
| Goldman et al, 2004 (54) | 24 | GSV | 100 | 6 (9‡) | NR |
| Proebstle et al, 2005 (55) | 223 | GSV | 92 | 3 | NR |
| Timperman et al, 2005 (56) | 100 | GSV | 91 | 9 | 1 |
| Puggioni et al, 2005 (40) | 77 | GSV/SSV | 94 | 1 | NR |
| Kabnick et al, 2006 (57) | 60 | GSV | 92 | 12 | NR |
| Almeida et al, 2006 (43) | 483/104 | GSV | 98 | 16‡ | 0.3‡ |
| Yang et al, 2006 (29) | 71 | GSV | 94 | 13 | NR |
| Kim et al, 2006 (58) | 60 | GSV | 95 | 3 | NR |
| Kavuturu et al, 2006 (59) | 66 | GSV? | 97 | 9 | NR |
| Meyers et al, 2006 (60) | 334 | GSV | * | 36 | NR |
| | 70 | SSV | | | |
| Sadick et al, 2007 (61) | 94 | GSV | 96 | 48 | NR |
| Theivacumar et al, 2007 (62) | 81 | GSV | 98 | 12 | NR |
| Gibson et al, 2007 (63) | 210 | SSV | 100 | 1.5 | NR |
| Ravi et al, 2006 (42) | 990 | GSV | 97 | 30–42 | NR |
| | 101 | SSV | 90 | 30–42 | NR |
| Desmyttere et al, (2007) (64) | 511 | GSV | 97 | 48 (34 limbs at 4 y) | NR |

Note.—NR = not reported.

* Survival determined by Kaplan-Meier analysis.

† EVL SFJ thrombus extension.

‡ Mean measurement.

Table 7
Anatomic Success at 1 Year*

| Treatment Type | Reported Range (%) | Action Threshold (%) |
|----------------|--------------------|----------------------|
| RF ablation | | |
| GSV | 68–100 | 80 |
| SSV | None | 80 |
| Laser ablation | | |
| GSV | 92–100 | 85 |
| SSV | 92 | 85 |
| Other veins† | None | 90 |

* Defined as duplex US disappearance of the entire treated vein segment.

† Remnant after surgery or accessory GSV.

Two comparisons of wavelength of delivered laser energy have been performed. One study compared 940 nm and 1,320 nm in a retrospective analysis

and another compared 810 nm and 980 nm in a randomized prospective study (55,57). Both studies demonstrated equivalent occlusion rates for the different wavelengths when used at similar rates of energy deposition. No differences in the complication rates were seen in patients treated with different wavelengths, but differences in the side effects of bruising and postprocedural discomfort were described. No randomized analysis evaluating outcomes and complications using differences in rate of energy delivery (Watts), linear energy deposition or fluence, controlling for other variables, has been performed.

EVTA success has been demonstrated in retrospective data review to be independent of vein diameter in many studies. However, a prospective confirmation of this conclusion has not been performed.

No prospective comparison of RF ablation and laser anatomic or clinical

rates has been performed. Several retrospective analyses of observational data have demonstrated qualitatively similar occlusion and complication rates (42,43,67). Anecdotally, bruising and discomfort have been thought to be less with continuous-mode laser deposition than with pulsed-mode deposition. This too has not been substantiated by published data.

Several studies have documented significant and durable improvements in validated assessments of QOL following EVTA. Two studies demonstrated significant improvements in the Aberdeen Varicose Veins Questionnaire (AVVQ), Short Form-36 (SF-36), and VCSS as long as 6 months following laser ablation (which were at least as good or better than the improvements seen following high ligation and stripping (HL/S) (68,69). VCSS scores were shown to decrease significantly in those patients treated with either laser or RF

Table 8
Comparison of EVTA and Surgery for GSV Reflux (64,68,69,72–78)

| Study, Year | Type | Limbs | Method | Follow-up | Results for RF Ablation Versus Surgery |
|------------------------------|--------------------|----------------|-----------------------|-----------|--|
| Rautio et al, 2002 (73) | RCT | 15 13 | RF HL/S | 50 d | 1. VAS pain score and med use less at 14 d 2. Less sick leave 3. RAND-36 pain score lower at 1 week but equal later 4. Duplex US closure rate, 100% 5. VSS and complications no different |
| Lurie et al, 2003 (64)* | RCT | 44 36 | RF HL/S | 4 months | 1. Time to normal activity, 1 d vs 4 d 2. Return to work, 5 d vs 12 d 3. CIVIQ2 better for RF at 1 week and 4 months 4. VCSS better for RF at 1 and 3 weeks, equal at 4 months 5. Duplex US closure rate, 91% 6. Equal complications |
| Lurie et al, 2005 (74)* | RCT | 44 36 | RF HL/S | 2 y | 1. Equal rates of new vessels (2% vs. 11%) 2. Equal recurrent varicose veins (14% vs. 21%) 3. CEAP improvement equal 4. VCSS better with RF at 72 h and 1 weeks, equal at 4 months and 2 y 5. QOL better with RF at 72 h, 1 weeks, and 1 and 2 y, equal at 3 weeks and 4 months 6. Duplex US: no reflux segments of GSV in 88% vs 92% |
| Perala et al, 2005 (75)* | RCT | 44 36 | RF HL/S | 2 y | 1. Equal VCSS, VDS, VSDS score improvements 2. Equal recurrent varicose veins and neovascularity |
| de Medeiros et al, 2005 (72) | Contralateral legs | 20 20† | HL/S HL/laser | 8 weeks | 1. More swelling/bruising with surgery 2. At 60 d, equivalent outcomes by QOL evaluation, APG 3. 70% favored laser, 10% felt treatments were equivalent |
| Stotter et al, 2005 (76) | RCT | 20 20 20 | RF HL/S HL/cryo | 1 y | 1. Duplex US: 90/100/90 2. VAS pain less for RF ablation 3. CIVIQ activity impairment better with RF to 1 y 4. RTW/RTA better for RF |
| Mekako et al, 2006 (68) | Case comparison | 62 70 | HL/S Laser | 12 weeks | 1. SF-36 better for laser at 1 and 6 weeks, equal at 12 weeks 2. AVVQ better for laser at 1, 6, and 12 weeks 3. VCSS improvements at 1, 6, and 12 weeks |
| Vulsteke et al, 2006 (77) | RCT | 84 80 | HL/S Laser | NR | 1. QOL, medication use, and sick days better for EVLT |
| Hinchliffe et al, 2006 (78) | RCT | — | HL/S RF | — | — |
| Rasmussen et al, 2007 (69) | RCT | 68 67 | Laser HL/S | 6 months | 1. Equivalent technical success, VAS, VSS, AVVQ, SF-36, duplex US |

Note.—APG = air plethysmography; AVVQ = Aberdeen Varicose Veins Questionnaire; HL = high ligation; HL/S = high ligation and stripping; NR = not reported; QOL = quality of life; RCT = randomized controlled trial.

* Same patients.

ablation and powered phlebectomy (67). Another study (57) demonstrated significant improvements in the VCSS 4 months after treatment with laser alone. Another study (70) demonstrated significant Aberdeen Varicose Veins Score improvement at 1 year following laser ablation, regardless of the number of

patent tributary branches found at the SFJ.

Evaluation of the effectiveness of EVTA in CEAP class 4–6 patients was performed in a retrospective review of patients 6 weeks after they were treated with RF ablation and laser (67). An 85% rate of vein occlusion was noted overall,

with significant improvements in venous clinical severity scores and air plethysmography findings. The correction in venous filling index on air plethysmography has been correlated with long-term symptomatic relief in surgical series (71). Marston et al (67) documented improvement in air plethys-

mography following EVTA at 6 weeks and de Medeiros and Luccas (72) at 8 weeks following ablation. Ulcer healing has been induced after EVLT. One report documented an 84% success with ulcer healing with a combination of either RF ablation or laser and microphlebectomy with 77% of these healing less than 2 weeks after the procedure (42).

Randomized Clinical Comparisons of EVTA and Surgery

As with any new treatment methodology, its acceptance as a standard of practice goes through an evolution from proof-of-concept studies to clinical comparisons to other existing standards of practice. Randomized and controlled data to compare the short-term and intermediate outcomes in patients with venous disease from truncal reflux treated with EVTA or HL/S are available at this time (Table 8).

Several small comparisons of EVTA using RF ablation and HL/S for the GSV have been performed (65,73,74,78). In the EVOLVEes sponsor-supported prospective randomized trial (65), postoperative pain was less severe, absence from work and return to normal activities was shorter, and physical function was restored faster after RF ablation at 4-month follow-up. At 2-year follow-up, recurrent varicose veins were found in 21% of patients treated with HL/S and 14% of patients treated with RF ablation, but this difference did not reach significance because of the small treatment populations (74). However, the likelihood of recurrence was 4.5 times higher in limbs with open GSV segments compared with those with successfully closed truncal veins, but this also did not achieve significance. In addition, at 2 years after treatment, the patients treated with RF ablation had maintained better QOL scores compared with the HL/S group (74).

Another small prospective randomized trial by Rautio et al (73) demonstrated less pain and more rapid recovery following GSV RF ablation compared with HL/S. Finally, clinical outcome and patient satisfaction were also better in the short term, but by 6 months these differences were no longer significant. The conclusions of these small randomized studies of surgery and RF ablation suggest equivalent out-

comes with shorter recovery periods for EVTA.

Several small comparison studies have evaluated the outcomes of laser ablation and surgery. In the first to be published (72), 20 patients with bilateral GSV reflux were treated with conventional HL/S on one leg and HL and laser in the other and then followed for 3 months. The patients were not informed which leg received which therapy, the choice of which technique was used was randomized, and all patients were treated with spinal or epidural anesthesia. No tumescent anesthetic was used. Early pain was similar for both procedures, although bruising and swelling was worse with surgery. All patients thought the aesthetic improvement was much better in both limbs but 70% thought the laser-treated limb benefited more, 20% the surgical limb, and 10% thought they were equal. Air plethysmography improvements were equivalent in both groups.

A nonrandomized consecutive treatment comparison of conventional HL/S with general anesthesia and laser ablation of the GSV using tumescent anesthesia has been performed (68). This study's goal was to compare the severity of venous disease and QOL changes at 1 and 12 weeks following laser treatment using the SF-36, Aberdeen Varicose Veins Questionnaire, and VCSS instruments. The authors demonstrated that, with the SF-36 at 1 and 6 weeks, the laser treatment recipients did not have the decrease in QOL seen in the surgical group at the same time. By 12 weeks, both groups had similar improvements in QOL and in an objective assessment of the severity of their venous disease. With the Aberdeen Varicose Veins Questionnaire, at 1 week, EVLT was similar in the decrease in QOL compared with surgery. However, at 6 and 12 weeks, QOL with laser treatment was significantly better than that with surgery. The VCSS improvement was significant compared with the pretreatment assessment and similar for both groups of patients.

A randomized comparison of 118 limbs treated with laser and microphlebectomy and 124 with conventional HL/S and microphlebectomy compared the QOL of the postprocedural period of both procedures (77). The study demonstrated significantly less postoperative morbidity for the laser procedure using the CIVIQ instrument of Launois. In ad-

dition, patient satisfaction, analgesia use, and number of days before return to work were significantly better for the laser-treated group.

A randomized trial of 68 limbs treated with HL/S and 62 with laser was performed with both groups being treated with only tumescent anesthesia (69). The preliminary report of this ongoing study evaluated the patients up to 6 months after their procedure using a variety of validated instruments including a visual analog scale of pain, VCSS, AVVSS and SF-36. Initial technical successes were equivalent. In this trial the early bruising and pain favored laser but by 3 months both procedures demonstrated significant improvements in all indices compared with pretreatment baselines; however, no differences were seen between HL/S and laser. One infection requiring antibiotics occurred in the surgical group. One patient in the laser group developed proximal extension of thrombus into the femoral vein that spontaneously resolved without treatment.

As previously mentioned, given that the case series have demonstrated a very high rate of treated vein disappearance following EVTA, it is likely that clinical recurrence will infrequently be related to failure of the EVTA. Recurrence in these cases will likely result from progression of the venous disease in other vein segments. However, randomized and controlled data to compare late clinical recurrence in patients treated with EVTA or HL/S to substantiate this assertion are not available at this time.

COMPLICATIONS

Adverse events following EVTA occur, but almost all are minor. Ecchymosis over the treated segment frequently occurs and normally can last for 14 days. Approximately 1 week after EVTA, the treated vein may develop a feeling of tightness similar to that after a strained muscle. This transient discomfort, likely related to inflammation in the treated vein segment, is self-limited and may be ameliorated with the use of nonsteroidal antiinflammatory drugs and graduated compression stockings. Both of these side effects are more commonly described after EVTA using existing laser protocols than for RF ablation, although direct objective blinded comparison has not been performed.

Table 9
Complications of EVTA*

| Complication | Reported Range (%) | Suggested Threshold (%) |
|--|--------------------|-------------------------|
| DVT | | |
| RF ablation | | |
| GSV | 0–16 | 5 |
| SSV | NR | 5 |
| Laser ablation | | |
| GSV | 0–8 | 2 |
| SSV | 0–6 | 5 |
| Paresthesia (temporary and permanent) | | |
| RF ablation | | |
| GSV | 0–15 | 10 |
| SSV | NR | 10 |
| Laser ablation | | |
| GSV | 0–12 | 10 |
| SSV | 0–10 | 10 |
| Skin burn | | |
| RF ablation | | |
| GSV | 0–7 | 1 |
| SSV | NR | 1 |
| Laser ablation | | |
| GSV | 0–12 | 1 |
| SSV | 0 | 1 |

Note.—NR = not reported separately.

* Complications other than those considered minor by SIR classification.

Superficial phlebitis is another uncommon side effect after EVTA, being reported after approximately 5% of procedures (48). There are no published reports of superficial phlebitis after EVTA progressing to DVT, and it has been managed in most series with non-steroidal antiinflammatory medication, graduated compression hose, and ambulation. Anecdotally, superficial phlebitis seems to be more common in larger-diameter dependent varicose veins or in varicose veins that have their inflow and outflow ablated by EVTA. Concurrent phlebectomy of these veins at the time of EVTA has been recommended to decrease the risk of this side effect, but at this point there are no data to substantiate this claim.

More significant AEs reported following EVTA include neurologic injuries, skin burns, and DVT (Table 9). The overall rate of these complications has been shown to be higher in low-volume centers compared with high-volume centers (36). The nerves at highest risk include the saphenous nerve, adjacent to the GSV below the midcalf perforat-

ing vein, and the sural nerve adjacent to the SSV in the mid- and lower calf. Both of these nerves have only sensory components. The most common manifestation of a nerve injury is a paresthesia or dysesthesia, most of which are transient. The nerve injuries can occur with sheath and catheter introduction, during the delivery of tumescent anesthesia, or by thermal injury related to heating of the perivenous tissues.

Tumescent anesthesia has been demonstrated to reduce perivenous temperatures with laser (79) and with RF ablation (41,80). The delivery of the perivenous fluid is believed to be responsible for the low rate of cutaneous and neurologic thermal injuries seen in the series of patients treated with it. An extremely high rate of nerve injuries and skin burns were reported in the article by Chang and Chua (20). This clearly was related to the use of extraordinarily high rates of energy delivery and direct treatment of varicose tributaries without the use of tumescent anesthetic treatment. Neurologic injuries are seen after truncal vein removal and are related to injury to nerves adjacent to the treated vein (81). Paresthesias caused by EVTA are mostly temporary. Excluding outliers, the rates of permanent paresthesias typically reported for laser EVTA of above-knee GSV are 0%–15%. Only a small number of series look at the SSV. The reported rates of temporary paresthesia following SSV EVTA are approximately 0%–10%.

The higher rates typically reported for RF ablation may be related to the fact that tumescent anesthesia was not commonly used with this procedure when some of the data were collected. The 1-week paresthesia rate following RF ablation was shown to decrease from 15% to 9% after the introduction of tumescent anesthesia (36). Patients treated with laser EVTA performed without tumescent anesthetic infiltrations exhibited a high rate of such injuries (20).

There is evidence suggesting a higher rate of nerve injuries reported when treating below-knee GSV with to the above-knee segment (32,33,82) and the SSV (36). Treatment of below-knee GSV or the lower part of the SSV may be necessary in many patients to treat to eliminate symptoms or skin disease caused by reflux to the ankle. A retrospective review (82) demonstrated that below-knee laser ablation can be performed with an 8% rate of mild but per-

manent paresthesias with adequate amounts of tumescent anesthesia. It is also suggested by these data that sparing the treatment of the distal 5–10 cm may accomplish clinical benefit and potentially avoid saphenous nerve injury risk in patients with reflux to the medial malleolus.

Skin burns following EVTA have been reported following RF and laser ablation. Skin burns are fortunately relatively rare and seem to be avoidable with adequate tumescent anesthesia. The rates of skin burn in one series (38) using RF ablation were 1.7% before and 0.5% after the initiation of the use of tumescent technique during RF ablation EVTA. The early experience had rates as high as 4% (33) that decreased to almost zero as the use of tumescent anesthesia became a standard of practice.

DVT following EVTA is unusual. DVT can occur as an extension of thrombus from the treated truncal vein across the junctional connection into the deep vein or in the calf or femoral popliteal veins. The reported rates of junctional thrombosis following GSV EVTA varies widely. This variability may relate to the time of the follow-up examination and the methods used. Most series using early duplex US (≤ 72 h after EVTA) document a proximal extension for the GSV of approximately 1% (Tables 5 and 6). Those performing the duplex US later identify a lower rate. It is possible the rates are different for different operators or that the proximal extension of thrombus is self limited without a clinical event. Pooling data from several sources suggests the incidences are approximately 0.3% after laser ablation and 0.4% after RF ablation (83). This type of DVT is almost universally asymptomatic. The significance of this type of thrombus extension into the femoral vein seems to be different that that with native GSV thrombosis with extension or compared with typical femoral vein thrombosis (84).

The incidence of junctional extension of thrombus after SSV ablation has been described to be low ($\leq 6\%$) (42,63). In one study (63), the rate of popliteal extension of SSV thrombus at 2–4 days after EVTA was thought to be related to the anatomy of the SPJ. The incidences were zero when no SPJ existed and 3% when a thigh extension existed, but 11% when no junctional vein could be identified.

The incidence of DVT in other pe-

ripheral deep veins after EVTA has not been well evaluated, as the results of routine scanning of the entire extremity are rarely described. However, the incidence of symptomatic DVT of the calf, popliteal, and femoral veins is very low.

Neovascularity at the SFJ after EVTA, as a form of recurrence of varicose veins, seems to be rare at 1–3-year follow-up (28,48,70). Neovascularization was seen in only two of the 1,222 limbs followed for up to 5 years in an industry-sponsored registry of patients treated with RF ablation (36). Longer follow-up may be necessary to feel confident with this observation; however, neovascularization following HL/S neovascularization is common and often an early event (8,85). A study was performed with the principal endpoint comparing the number of vessels seen before and 1 year after laser ablation (70). At 1 year there was a 98% success rate in vein occlusion, with 97% of the occluded veins becoming invisible by this point. Neovascularity was found in only one patient. In all the others, there was either flush occlusion to the SFJ (40%) or one or more competent tributaries in continuity with the SFJ (59%) (70).

Anecdotal reports of laser fiber fracture or retained venous access sheaths have been made to the device manufacturers, and a case report exists describing a retained vascular sheath after laser ablation (86). Respecting the fragile glass laser fibers and being gentle with its handling should help minimize laser fiber fractures. The possibility of a laser fiber fracture should be considered with the removal of the device in each case. Care to deliver thermal energy only beyond the introducer sheath and away from any other parallel placed sheath is essential to avoid severing segments of these catheters. No specific management recommendations of retained intravenous laser fiber or sheath fragments can be made based on the data.

A case report of an arteriovenous fistula between a small popliteal artery branch and the SSV exists (87). Anecdotal references have been made of additional arteriovenous fistulas between the proximal GSV and the contiguous superficial external pudendal artery. Although thought to be related to a heat-induced injury caused by the thermal device, an arteriovenous fistula could be caused by a needle injury during tumescent anesthetic administration. Ways to

minimize the risk of these arteriovenous fistulas include careful advancement of the intravascular devices, atraumatic delivery of the tumescent anesthetic fluid, the use of copious amounts of tumescent fluid, and avoidance of treating the subfascial portion of the SSV where popliteal artery branches exist.

CONCLUSIONS

EVTA is one of several potential treatment options for patients with SVI. It can safely, effectively, and durably eliminate reflux in truncal veins using only local anesthesia. Successful outcomes require a thorough understanding of the disease process and the anatomy of the superficial venous system. A thorough examination with Duplex US is essential to make the correct diagnosis. Treatment planning, technical details, and postprocedural care unique to this procedure are important to understand.

Acknowledgments: Neil M. Khilnani, MD, authored the first draft of this document and served as topic leader during the subsequent revisions of the draft. Clement J. Grassi, MD, is chair of the SIR Standards of Practice Committee. John F. Cardella, MD, is Councilor of the SIR Standards Division. All other authors are listed alphabetically. Other members of the Standards of Practice Committee and SIR who participated in the development of this clinical practice guideline are as follows: Sanjoy Kundu, MD, John "Fritz" Angle, MD, Ganesh Annamalai, MD, Stephen Balter, PhD, Daniel B. Brown, MD, Danny Chan, MD, Timothy W.I. Clark, MD, MSc, Bairbre L. Connolly, MD, Brian D. Davison, MD, Peter Drescher, MD, Debra Ann Gervais, MD, S. Nahum Goldberg, MD, Manraj K.S. Heran, MD, Maxim Itkin, MD, Sanjeeva P. Kalva, MD, Patrick C. Malloy, MD, Tim McSorley, BS, RN, CRN, Philip M. Meyers, MD, Charles A. Owens, MD, Dheeraj K. Rajan, MD, Anne C. Roberts, MD, Steven C. Rose, MD, Tarun Sabharwal, MD, Nasir H. Siddiqui, MD, LeAnn Stokes, MD, Patricia E. Thorpe, MD, Richard Towbin, MD, Aradhana Venkatesan, MD, Louis K. Wagner, PhD, Michael J. Wallace, MD, Joan Wojak, MD, Darryl A. Zuckerman, MD, Curtis W. Bakal, MD, Curtis A. Lewis, MD, MBA, JD, Kenneth S. Rholl, MD, David Sacks, MD, Thierry de Baere, MD, Fabricio Fanelli, MD, Alexis Kelekis, MD, and Manuel Maynar, MD

References

1. Caggiati A, Bergan JJ, Gloviczki P, Jantet G, Wendell-Smith CP, Partsch H, for the International Interdisciplinary Consensus Committee on Venous Anatomical Terminology. Nomenclature

of the veins of the lower limbs: an international interdisciplinary consensus statement. *J Vasc Surg* 2002; 36:416–422.

2. Caggiati A, Bergan JJ, Gloviczki P, Eklof B, Allegra C, Partsch H, for the International Interdisciplinary Consensus Committee on Venous Anatomical Terminology. Nomenclature of the veins of the lower limb: extensions, refinements, and clinical application. *J Vasc Surg* 2005; 41:719–724.
3. Nicolaidis AN, Hussein MK, Szendro G, Christopoulos D, Vasdekis S, Clarke H. The relation of venous ulceration with ambulatory venous pressure measurements. *J Vasc Surg* 1993; 17:414–419.
4. Kistner RL, Eklof B, Masuda EM. Diagnosis of chronic venous disease of the lower extremities: the CEAP classification. *Mayo Clinic Proc* 1996; 71:338–345.
5. Labropoulos N, Delis K, Nicolaidis AN, Leon M, Ramaswami G, Volteas N. The role of the distribution and anatomic extent of reflux in the development of signs and symptoms in chronic venous insufficiency. *J Vasc Surg* 1996; 23:504–510.
6. Labropoulos N. Clinical correlation to various patterns of reflux. *J Vasc Surg* 1997; 31:242–248.
7. Meissner M, Caps MT, Zierler B, et al. Determinants of chronic venous disease after acute deep vein thrombosis. *Vasc Surg* 1998; 28:826–833.
8. Jones L, Braithwaite BD, Selwyn D, Cooke S, Earnshaw JJ. Neovascularization is the principle cause for varicose vein recurrence: results of a randomized trial of stripping the long saphenous vein. *Eur J Vasc Endovasc Surg* 1996; 12:442–445.
9. Labropoulos N. CEAP in clinical practice. *J Vasc Surg* 1997; 31:224–225.
10. Rutherford RB, Padberg FT Jr, Comerota AJ, et al. Venous severity scoring: an adjunct to venous outcome assessment. *J Vasc Surg* 2000; 31:1307–1312.
11. Nguyen T, Bergan J, Min R, Morrison N, Zimmet S. Curriculum of the American College of Phlebology. *Phlebology* 2006; 21(suppl 2):1–20.
12. Kurz X, Kahn SR, Abenhein L, et al. Chronic venous disorders of the leg: epidemiology, outcomes, diagnosis and management. Summary of an evidence-based report of the VEINES task force (Venous Insufficiency Epidemiologic and Economic Studies). *Int Angiol* 1999; 18:83–102.
13. Coleridge-Smith P, Labropoulos N, Partsch H, Myer K, Nicolaidis A, Cavezzi A. Duplex ultrasound investigation of the veins in chronic venous disease of the lower limbs—UIP consensus document. Part 1: basic principles. *Phlebology* 2006; 21:158–167.

14. Bergan J, Min R, Zimmet S, Zygmunt J. Duplex ultrasound imaging of lower extremity veins in chronic venous disease, exclusive of deep venous thrombosis: guideline for performance and interpretation of studies; ACP Guideline, April 2006. San Leandro, CA: American College of Phlebology, 2006.
15. Min RJ, Khilnani NM, Golia P. Duplex ultrasound evaluation of lower extremity venous insufficiency. *J Vasc Interv Radiol* 2003; 14:1233-1241.
16. Cavezzi A, Labropoulos N, Partsch H, et al. Duplex ultrasound investigation of the veins in chronic venous disease of the lower limbs—UIP consensus document. Part 2: anatomy. *Eur J Vasc Endovasc Surg* 2006; 31:288-299.
17. Ahmad I, Ahmad W, Dingui M. Prevention or reversal of deep venous insufficiency by aggressive treatment of superficial venous disease. *Am J Surg* 2006; 191:33-38.
18. Peden E, Lumsden A. Radiofrequency ablation of incompetent perforator veins. *Perspect Vasc Surg Endovasc Ther* 2007; 19:73-77.
19. Chang C, Chua J. Endovenous laser photocoagulation (EVLP) for varicose veins. *Lasers Surg Med* 2002; 31:257-262.
20. Chong PFS, Kumar R, Kushwaha R, Sweeney A, Chaloner EJ. Technical tip: cold saline infiltration instead of local anaesthetic in endovenous laser treatment. *Phlebology* 2006; 21:88-89.
21. Malloy PC, Grassi CJ, Kundu S, et al. Consensus guidelines for periprocedural management of coagulation status and hemostasis risk in percutaneous image-guided interventions. *J Vasc Interv Radiol* 2009; 20:S240-S249.
22. Theivacumar NS, Gough MJ. Influence of warfarin on the success of endovenous laser ablation (EVLA) of the great saphenous vein (GSV). *Eur J Vasc Endovasc Surg* 2009; 38:506-510.
23. Proebstle TM, Gul D, Lehr HA, et al. Infrequent early recanalization of greater saphenous vein after endovenous laser treatment. *J Vasc Surg* 2003; 38:511-516.
24. Yu SS, Tope WD, Grekin RC. Cardiac devices and electromagnetic interference revisited: new radiofrequency technologies and implications for dermatologic surgery. *Dermatol Surg* 2005; 31:932-940.
25. Monahan DL. Can phlebectomy be deferred in the treatment of varicose veins? *J Vasc Surg* 2005; 42:1145-1149.
26. Welch HJ. Endovenous ablation of the great saphenous vein may avert phlebectomy for branch varicose veins. *J Vasc Surg* 2006; 44:601-605.
27. Kundu S, Lurie F, Millward SF, et al. Recommended reporting standards for percutaneous ablation for the treatment of venous insufficiency: Joint Statement of the American Venous Forum and the Society of Interventional Radiology. *J Vasc Interv Radiol* 2007; 18:1073-1080.
28. Pichot O, Kabnick LS, Creton D, Merchant RF, Schuller-Petroviae S, Chandler JG. Duplex ultrasound scan findings two years after great saphenous vein radiofrequency endovenous obliteration. *J Vasc Sug* 2004; 39:189-195.
29. Yang CH, Chou HS, Lo YF. Incompetent great saphenous veins treated with endovenous 1,320-nm laser: results for 71 legs and morphologic evolution study. *Dermatol Surg* 2006; 32:1453-1457.
30. Goldman MP. Closure of the greater saphenous veins with endoluminal radiofrequency thermal heating of the vein wall in combination with ambulatory phlebectomy: preliminary 6-month follow-up. *Dermatol Surg* 2000; 26:452-456.
31. Goldman MP, Amiry S. Closure of the greater saphenous veins with endoluminal radiofrequency thermal heating of the vein wall in combination with ambulatory phlebectomy: 50 patients with more than 6-month follow-up. *Dermatol Surg* 2002; 28:29-31.
32. Weiss RA, Weiss MA. Controlled radiofrequency endovenous occlusion using a unique radiofrequency catheter under duplex guidance to eliminate saphenous varicose vein reflux: a 2 year follow-up. *Dermatol Surg* 2002; 28:38-42.
33. Merchant RF, dePalma RG, Kabnick LS. Endovascular obliteration of saphenous reflux: a multicenter study. *J Vasc Surg* 2002; 35:1180-1186.
34. Wagner WH, Levin PM, Cossman DV, Lauterbach SR, Cohen JL, Farber A. Early experience with radiofrequency ablation of the greater saphenous vein. *Ann Vasc Surg* 2004; 18:42-47.
35. Hingorani AP, Ascher E, Markevich N, et al. Deep vein thrombosis after radiofrequency ablation of the greater saphenous vein: a word of caution. *J Vasc Surg* 2004; 40:500-504.
36. Merchant RF, Pichot O, for the Closure Study Group. Long-term outcomes of endovenous radiofrequency obliteration of saphenous reflux as a treatment of superficial venous insufficiency. *J Vasc Surg* 2005; 42:502-509.
37. Nicolini P, the Closure Group. Treatment of primary varicose veins by endovenous obliteration by the Closure system: results of a prospective multicentre study. *Eur J Vasc Endovasc Surg* 2005; 29:433-439.
38. Merchant RF, Pichot O, Meyers KA. Four-year follow-up on endovascular radiofrequency obliteration of great saphenous reflux. *Dermatol Surg* 2005; 31:129-134.
39. Mozes G, Kalra M, Carmo M, Swenson L, Gloviczki P. extension of saphenous thrombus into the femoral vein: a potential complication of new endovenous ablation techniques. *J Vasc Surg* 2005; 41:130-135.
40. Puggioni A, Kalra M, Carmo M, Mozes G, Gloviczki P. Endovenous laser therapy and radiofrequency ablation of the great saphenous vein: analysis of early efficacy and complications. *J Vasc Surg* 2005; 42:488-493.
41. Dunn CW, Kabnick LS, Merchant RF, Owens R, Weiss RA. Endovascular radiofrequency obliteration using 90°C for treatment of great saphenous vein. *Ann Vasc Surg* 2006; 20:625-629.
42. Ravi R, Rodriguez-Lopez JA, Trayler EA, Barrett DA, Ramaiah V, Diethrich EB. Endovenous ablation of incompetent saphenous veins: a large single-center experience. *J Endovasc Ther* 2006; 13:244-248.
43. Almeida JI, Raines JK. Radiofrequency ablation and laser ablation in the treatment of varicose veins. *Ann Vasc Surg* 2006; 20:547-552.
44. Proebstle TM, Vago B, Alm J, Gockeritz O, Lebard C, Pichot O, for the Closure Fast Clinical Study. Treatment of the incompetent great saphenous vein by endovenous radiofrequency powered segmental thermal ablation: first clinical experience. *J Vasc Surg* 2008; 47:151-156.
45. Navarro L, Min RJ, Bone C. Endovenous laser: a new minimally invasive method of treatment of varicose veins—preliminary observations using an 810nm diode laser. *Dermatol Surg* 2001; 27:117-122.
46. Min RJ, Zimmet SE, Isaacs MN, Forrestal MD. Endovenous treatment of the incompetent greater saphenous vein. *J Vasc Interv Radiol* 2001; 12:1167-1171.
47. Oh CK, Jung DS, Jang HS, Kwon KS. Endovenous laser surgery of incompetent greater saphenous vein with a 980-nm diode laser. *Dermatol Surg* 2003; 29:1135-1140.
48. Min RJ, Khilnani NM, Zimmet SE. Endovenous laser treatment of saphenous vein reflux: long-term results. *J Vasc Interv Radiol* 2003; 14:991-996.
49. Proebstle TM, Gul D, Kargl A, Knop J. Endovenous laser treatment of the lesser saphenous vein with a 940-nm diode laser: early results. *Dermatol Surg* 2003; 29:357-361.
50. Perkowski P, Ravi R, Gowda RCN, et al. Endovenous laser ablation of the saphenous vein for treatment of venous insufficiency and varicose veins: early results from a large single-center experience. *J Endovasc Ther* 2004; 11:132-138.
51. Sadick NS, Waser S. Combined endovascular laser with ambulatory phlebectomy for the treatment of superficial venous incompetence: a 2-year

- perspective. *J Cosmet Laser Ther* 2004; 24:149–153.
52. Timperman PE, Sichlau M, Ryu RK. Greater energy delivery improves treatment success of endovenous laser treatment of incompetent saphenous veins. *J Vasc Interv Radiol* 2004; 10:1061–1063.
 53. Proebstle TM, Krummenauer F, Gul D, et al. Nonocclusion and early reopening of the great saphenous vein after endovenous laser treatment is fluence dependent. *Dermatol Surg* 2004; 30:174–178.
 54. Goldman MP, Mauricio M, Rao J. Intravascular 1320-nm laser closure of the great saphenous vein: a 6 to 12-month follow-up study. *Dermatol Surg* 2004; 30:1380–1385.
 55. Proebstle TM, Moehler T, Gul D, Herdemann S. Endovenous treatment of the great saphenous vein using a 1,320 nm Nd:YAG laser causes fewer side effects than using a 940 nm diode laser. *Dermatol Surg* 2005; 31:1678–1683.
 56. Timperman PE. Prospective evaluation of higher energy great saphenous vein endovenous laser treatment. *J Vasc Interv Radiol* 2005; 16:791–794.
 57. Kabnick LS. Outcome of different endovenous laser wavelengths for great saphenous vein ablation. *J Vasc Surg* 2006; 43:88–93.
 58. Kim HS, Paxton BE. Endovenous laser ablation of the great saphenous vein with a 980-nm diode laser in continuous mode: early treatment failures and successful repeat treatments. *J Vasc Interv Radiol* 2006; 17:1449–1455.
 59. Kavuturu S, Girishkumar H, Ehrlich F. Endovenous laser ablation of saphenous veins is an effective treatment modality for lower extremity varicose veins. *Am Surg* 2006; 72:672–675.
 60. Myers K, Fris R, Jolley D. Treatment of varicose veins by endovenous laser therapy: assessment of results by ultrasound surveillance. *Med J Austral* 2006; 185:199–202.
 61. Sadick NS, Wasser S. Combined endovascular laser plus ambulatory phlebectomy for the treatment of superficial venous incompetence: a 4-year perspective. *J Cosmet Laser Ther* 2007; 9:9–13.
 62. Theivacumar NS, Beale RJ, Mavor AJ, Gough MJ. Initial experience in endovenous laser ablation (EVLA) of varicose veins due to small saphenous vein reflux. *Eur J Vasc Endovasc Surg* 2007; 33:614–618.
 63. Gibson KD, Ferris BL, Polissar N, Neradilek B, Pepper D. Endovenous laser treatment of the short saphenous vein: efficacy and complications. *J Vasc Surg* 2007; 45:795–801.
 64. Desmyttere J, Grand C, Wassmer B, Mordon S. Endovenous 980-nm laser treatment of saphenous veins in a series of 500 patients. *J Vasc Surg* 2007; 46:1242–1247.
 65. Lurie F, Creton D, Eklof B, et al. Prospective randomized study of endovenous radiofrequency obliteration (closure procedure) versus ligation and stripping in a selected patient population (EVOLVeS Study). *J Vasc Surg* 2003; 38:207–214.
 66. Dwerryhouse S, Davies B, Harradine K, Earnshaw JJ. Stripping the long saphenous vein reduced the rate of reoperation for recurrent varicose veins: five-year results of a randomized trial. *J Vasc Surg* 1999; 24:589–592.
 67. Marston WA, Owens LV, Davies S, Mendes RR, Farber MA, Keagy BA. Endovenous saphenous ablation corrects the hemodynamic abnormality in patients with CEAP clinical class 3–6 CVI due to superficial reflux. *Vasc Endovasc Surg* 2006; 40:125–130.
 68. Mekako AI, Hatfield J, Bryce J, et al. A nonrandomized controlled trial of endovenous laser therapy and surgery in the treatment of varicose veins. *Ann Vasc Surg* 2006; 20:451–457.
 69. Rasmussen LH, Bjoern L, Lawaetz M, et al. Randomized trial comparing endovenous laser ablation of the great saphenous vein with high ligation and stripping in patients with varicose veins: short term results. *J Vasc Surg* 2007; 46:308–315.
 70. Theivacumar NS, Dellagrammaticas D, Beale RJ, Mavor AJ, Gough MJ. Fate and clinical significance of saphenofemoral junction tributaries following endovenous laser ablation of great saphenous vein. *Br J Surg* 2007; 94:722–725.
 71. Owens LV, Farber MA, Young ML, et al. The value of air plethysmography in predicting clinical outcome after surgical treatment of chronic venous insufficiency. *J Vasc Surg* 2000; 32:961–968.
 72. de Medeiros, Luccas GC. Comparison of endovenous treatment with an 810 nm laser versus conventional stripping of the great saphenous vein in patients with primary varicose veins. *Derm Surg* 2005; 31:1685–1694.
 73. Rautio T, Ohinmaa A, Perala J, et al. Endovenous obliteration versus conventional stripping operation in the treatment of primary varicose veins: a randomized controlled trial with comparison of the costs. *J Vasc Surg* 2002; 35:958–965.
 74. Lurie F, Creton D, Eklof B, et al. Prospective randomized study of endovenous radiofrequency obliteration (Closure) versus ligation and stripping (EVOLVeS): two-year follow-up. *Eur J Vasc Endovasc Surg* 2005; 29:67–73.
 75. Perala J, Ratio T, Biancari F, et al. Radiofrequency endovenous obliteration versus stripping of the long saphenous vein in the management of primary varicose veins: 3-year outcome of a randomized study. *Ann Vasc Surg* 2005; 19:669–672.
 76. Stotter L, Schaaf I, Bockelbrink A. Comparative outcomes of radiofrequency endoluminal ablation, invagination stripping, and cryostripping in the treatment of great saphenous vein insufficiency. *Phlebology* 2006; 21:60–64.
 77. Vuylsteke M, Van den Bussche D, Audenaert EA, Lissens P. Endovenous obliteration for the treatment of primary varicose veins. *Phlebology* 2006; 21:80–87.
 78. Hinchliffe RJ, Ubhi J, Beech A, et al. A prospective randomized controlled trial of VNUS closure versus surgery for the treatment of recurrent long saphenous veins. *Eur J Vasc Endovasc Surg* 2006; 31:212–218.
 79. Zimmet SE, Min RJ. Temperature changes in perivenous tissue during endovenous laser treatment in a swine model. *J Vasc Interv Radiol* 2003; 14:911–915.
 80. Zikorus AW, Mirizzi MS. Evaluation of setpoint temperature and pullback speed on vein adventitial temperature during endovenous radiofrequency energy delivery in an in-vitro model. *Vasc Endovascular Surg* 2004; 38:167–174.
 81. Morrison C, Dalsing MC. Signs and symptoms of saphenous nerve injury after greater saphenous vein stripping: prevalence, severity and relevance for modern practice. *J Vasc Surg* 2003; 38:886–890.
 82. Timperman PE. Endovenous laser treatment of incompetent below-knee great saphenous vein. *J Vasc Interv Radiol* 2007; 18:1495–1499.
 83. Merchant RF, Kistner RL, Kabnick LS. Re: "Is there an increased risk for DVT after the Closure procedure?" *J Vasc Surg* 2003; 38:628.
 84. Kabnick LS, Ombrellino M, Agis H, et al. Endovenous heat induced thrombus (EHIT) at the superficial-deep venous junction: a new post-treatment clinical entity, classification and patient treatment strategies [abstract]. Presented at the American Venous Forum 18th Annual Meeting; February 23, 2006; Miami, FL.
 85. van Rij AM, Jones GT, Hill GB, Jiang P. Neovascularization and recurrent varicose veins: more histologic and ultrasound evidence. *J Vasc Surg* 2004; 40:296–302.
 86. Ravi R, Bhutani A, Diethrich EB. "No sheath left behind." *J Endovasc Ther* 2007; 14:265–267.
 87. Timperman PE. Arteriovenous fistula after endovenous laser treatment of the short saphenous vein. *J Vasc Interv Radiol* 2004; 15:625–627.

SIR DISCLAIMER

The clinical practice guidelines of the Society of Interventional Radiology attempt to define practice principles that generally should assist in producing high quality medical care. These guidelines are voluntary and are not rules. A physician may deviate from these guidelines, as necessitated by the individual patient and available resources. These practice guidelines should not be deemed inclusive of all proper methods of care or exclusive of other methods of care that are reasonably directed towards the same result. Other sources of information may be used in conjunction with these principles to produce a process leading to high quality medical care. The ultimate judgment regarding the conduct of any specific procedure or course of management must be made by the physician, who should consider all circumstances relevant to the individual clinical situation. Adherence to the SIR Quality Improvement Program will not assure a successful outcome in every situation. It is prudent to document the rationale for any deviation from the suggested practice guidelines in the department policies and procedure manual or in the patient's medical record.

CME TEST QUESTIONS

Examination available at <http://directory.sirweb.org/jvircme>



The CME questions in this issue are derived from Khilnani et al, Multi-Society Consensus Quality Improvement Guidelines for the Treatment of Lower Extremity Superficial Venous Insufficiency With Endovenous Thermal Ablation.

1. Which of the following terms best describes a superficial vein running from the lateral aspect of the foot and draining into the popliteal vein?
 - a. Great saphenous vein
 - b. Giacomini vein
 - c. Posterior accessory great saphenous vein
 - d. Small saphenous vein

2. A patient you are seeing in the vein clinic for consideration of treatment of superficial venous insufficiency is noted to have brownish darkening of the skin and clusters of small (<1 mm width) intradermal venules at the medial ankle. What CEAP (Clinical severity, Etiology, Anatomy, Pathophysiology) clinical grade would you record for this patient?
 - a. Grade 3
 - b. Grade 4a
 - c. Grade 4b
 - d. Grade 5

3. Which of the following treatment strategies for symptomatic superficial venous insufficiency does this quality improvement guideline discourage?
 - a. Treatment of competent vein segments below an incompetent vein segment
 - b. Treatment of incompetent superficial truncal veins in the setting of deep vein reflux
 - c. Treatment of an incompetent truncal vein with reflux of greater than 0.5 sec duration
 - d. Treatment of a great saphenous vein measuring 1.0 cm in diameter

4. What is the suggested action threshold for skin burn following endovascular thermal ablation for lower extremity venous insufficiency?
 - a. 0.5%
 - b. 1%
 - c. 2%
 - d. 5%